

MSB

# FORCEPS

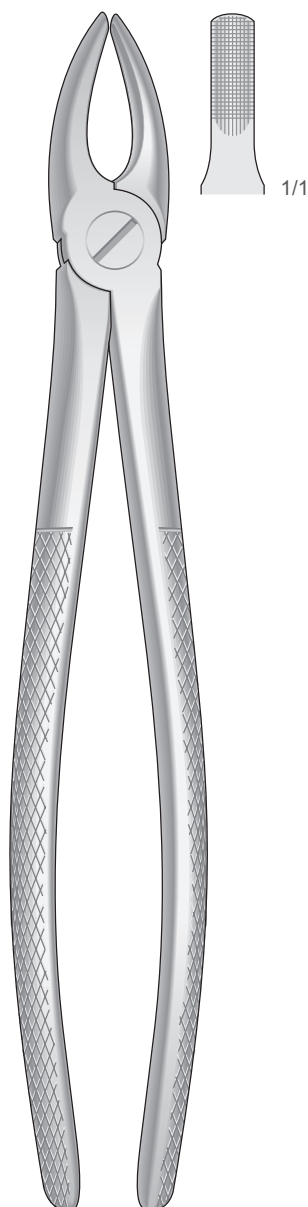


## Extracting Forceps, English Pattern

Zahnzangen, Englische Form  
 Pinze per estrazione, Forma Inglese  
 Pinzas da extracción, Forma Inglesa  
 Daviers, Forme Anglaise

## Forceps

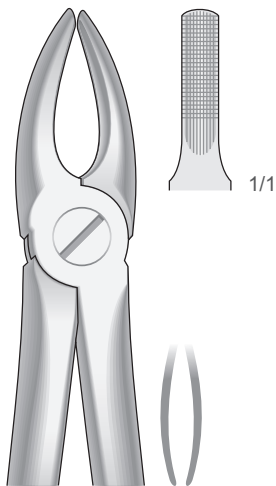
Pinzetten  
 Pinzas  
 Pincas  
 Pinzei



1

Fig. 1

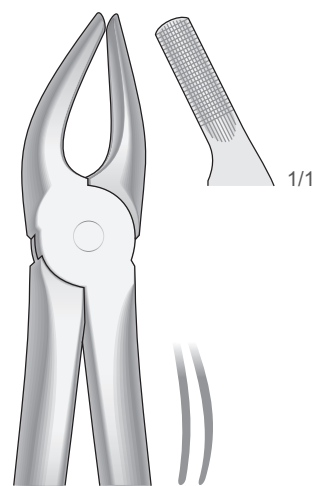
Obere Schneide- und Eckzähne  
 Upper Incisors and cuspids  
 Incisivi e canini superiori  
 Incisivos y caninos superiores  
 Incisives et canines supérieures



2

Fig. 2

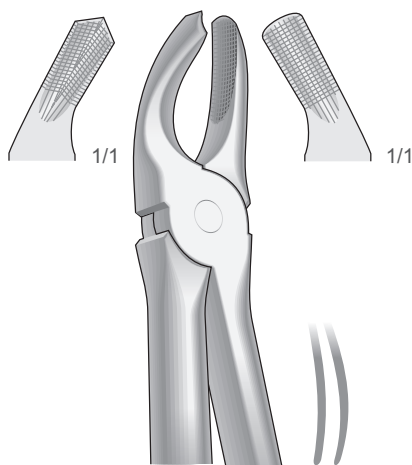
Obere Schneide- und Eckzähne  
 Upper Incisors and cuspids  
 Incisivi e canini superiori  
 Incisivos y caninos superiores  
 Incisives et canines supérieures



7

Fig. 7

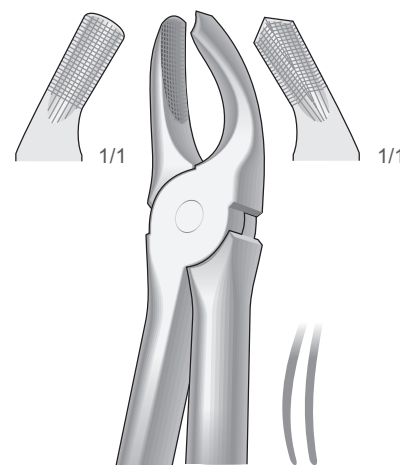
Obere Prämolaren  
 Upper premolars  
 Premolari superiori  
 Premolares superiores  
 Prémolaires supérieures



17

Fig. 17

Obere Molaren, rechts  
 Upper molars, right  
 Molari superiori, destra  
 Molares superiores, derechos  
 Molaires supérieures, droites



18

Fig. 18

Obere Molaren, links  
 Upper molars, left  
 Molari superiori, sinistra  
 Molares superiores, izquierdos  
 Molaires supérieures, gauches

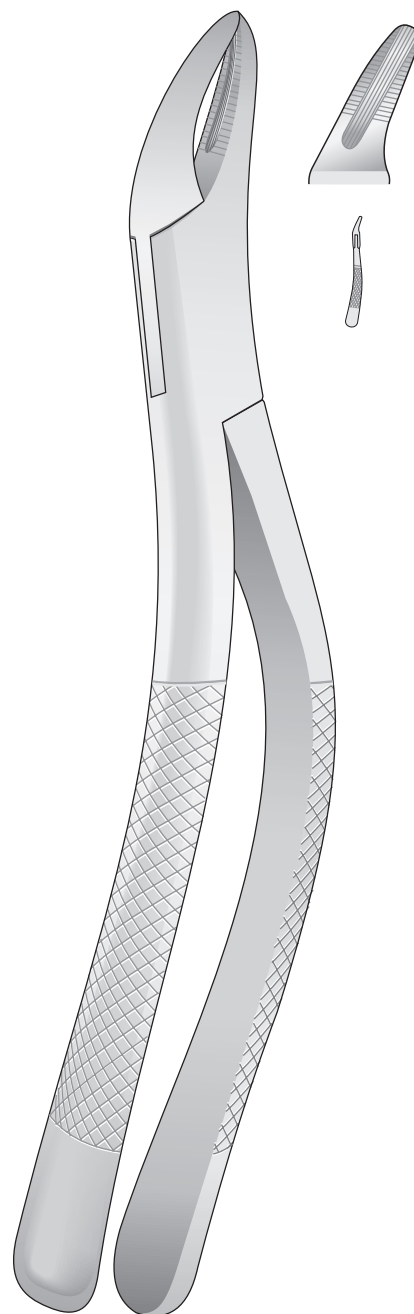
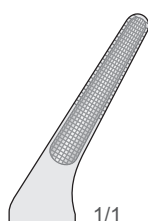
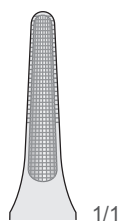
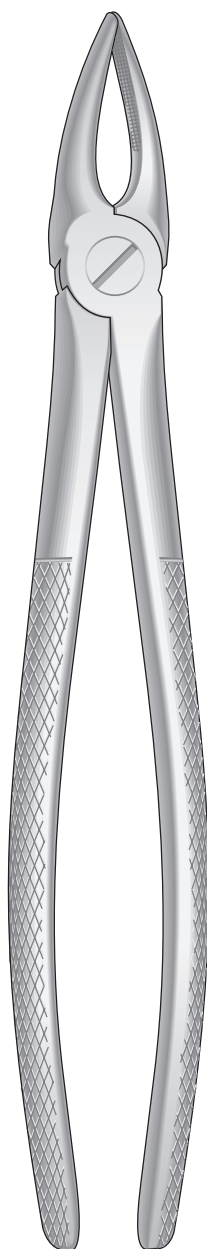
## Extracting Forceps, English Pattern

Zahnzangen, Englische Form

Pinze per estrazione, Forma Inglese

Pinzas da extracción, Forma Inglesa

Daviers, Forme Anglaise



**29**

Fig. 29

Obere Wurzeln und Schneidezähne  
Upper Roots and incisors  
Radici e incisivi superiori  
Raíces y incisivos superiores  
Racines et incisives supérieures

**30**

Fig. 30

Obere Wurzeln  
Upper Roots  
Radici superiori  
Raíces superiores  
Racines supérieures

**76S**

Fig. 76

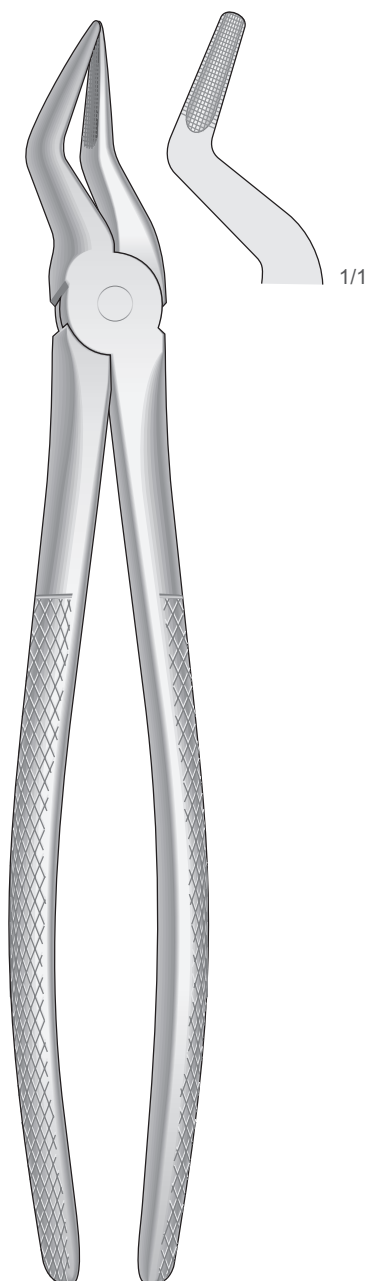
Obere Schneidezähne, Prämolaren, Wurzeln  
Upper incisors, premolars, roots  
Incisivi, premolari e radici superiori  
Incisivos, premolares y raíces superiores  
Incisives, prémolaires et racines supérieures

## Extracting Forceps, English Pattern

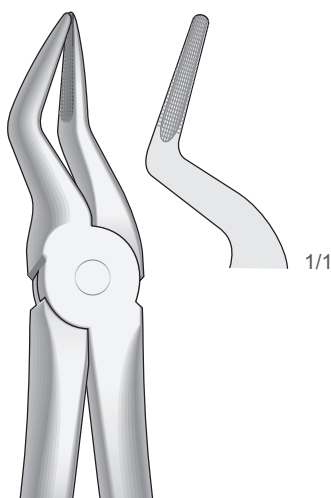
Zahnzangen, Englische Form  
Pinze per estrazione, Forma Inglese  
Pinzas da extracción, Forma Inglesa  
Daviers, Forme Anglaise

## Forceps

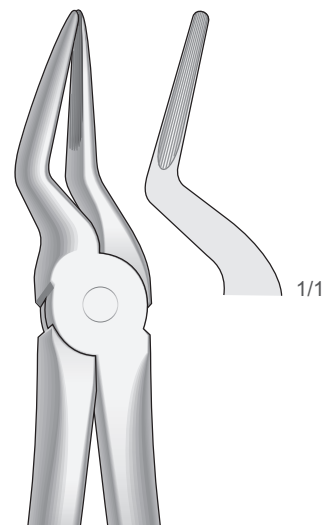
Pinzetten  
Pinzas  
Pinces  
Pinzei



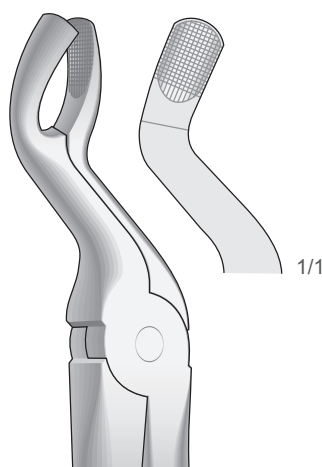
**51**  
Fig. 51  
Obere Wurzeln  
Upper Roots  
Radici superiori  
Raíces superiores  
Racines supérieures



**51A**  
Fig. 51A  
Obere Wurzeln  
Upper Roots  
Radici superiori  
Raíces superiores  
Racines supérieures



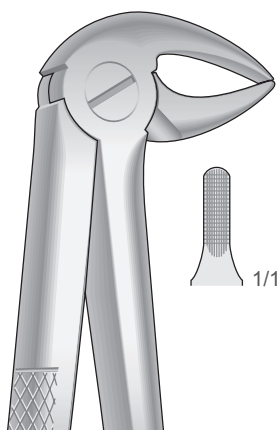
**51L**  
Fig. 51AL  
Obere Wurzeln  
Upper Roots  
Radici superiori  
Raíces superiores  
Racines supérieures



**67A**  
Fig. 67A  
Obere Dritte Molaren - Für Obere Weisheitszähne  
Upper molars - For Upper wisdom teeth  
Ottavi superiori - Per denti del giudizio superiori  
Molares superiores - Para muelas del juicio superiores  
Molaires supérieures - Pour dents de sagesse supérieures

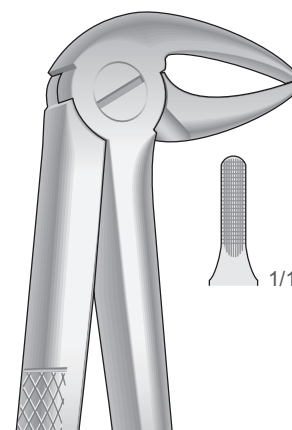
## Extracting Forceps, English Pattern

Zahnzangen, Englische Form  
 Pinze per estrazione, Forma Inglese  
 Pinzas da extracci6n, Forma Inglesa  
 Daviers, Forme Anglaise



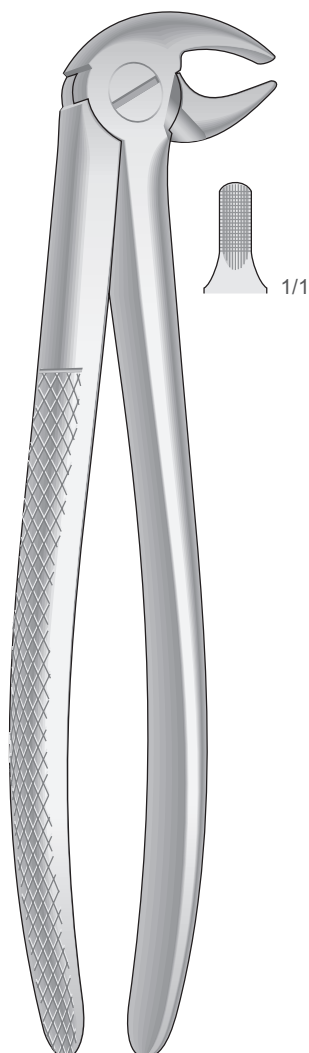
**33**  
 Fig. 33

Untere Prämolaren, Schneidezähne und Wurzeln  
 Lower incisors, premolars and roots  
 Incisivi, premolari e radici inferiori  
 Incisivos, premolares y raíces inferiores  
 Incisives, prémolaires et racines inférieures



**33A**  
 Fig. 33A

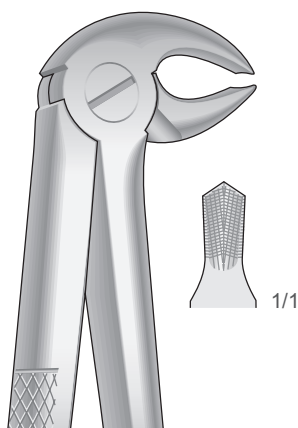
Untere Wurzeln, schlankes Maul  
 Lower roots, Slender jaw  
 Radici inferiori, morso stretto  
 Raíces inferiores, boca estrecha  
 Racines inférieures, avec un bec très fin



**13**

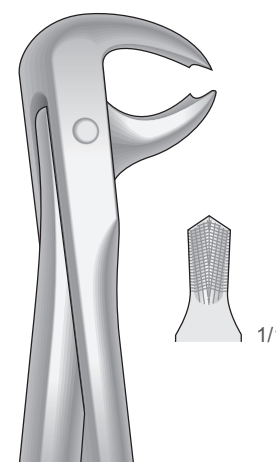
Fig. 13

Untere Eckzähne und Prämolaren  
 Lower cuspids and premolars  
 Canini e premolari inferiori  
 Caninos y premolares inferiores  
 Canines et prémolaires inférieures



**22**  
 Fig. 22

Untere Molaren  
 Lower molars  
 Molari inferiori  
 Molares inferiores  
 Molaires inférieures



**73**  
 Fig. 73

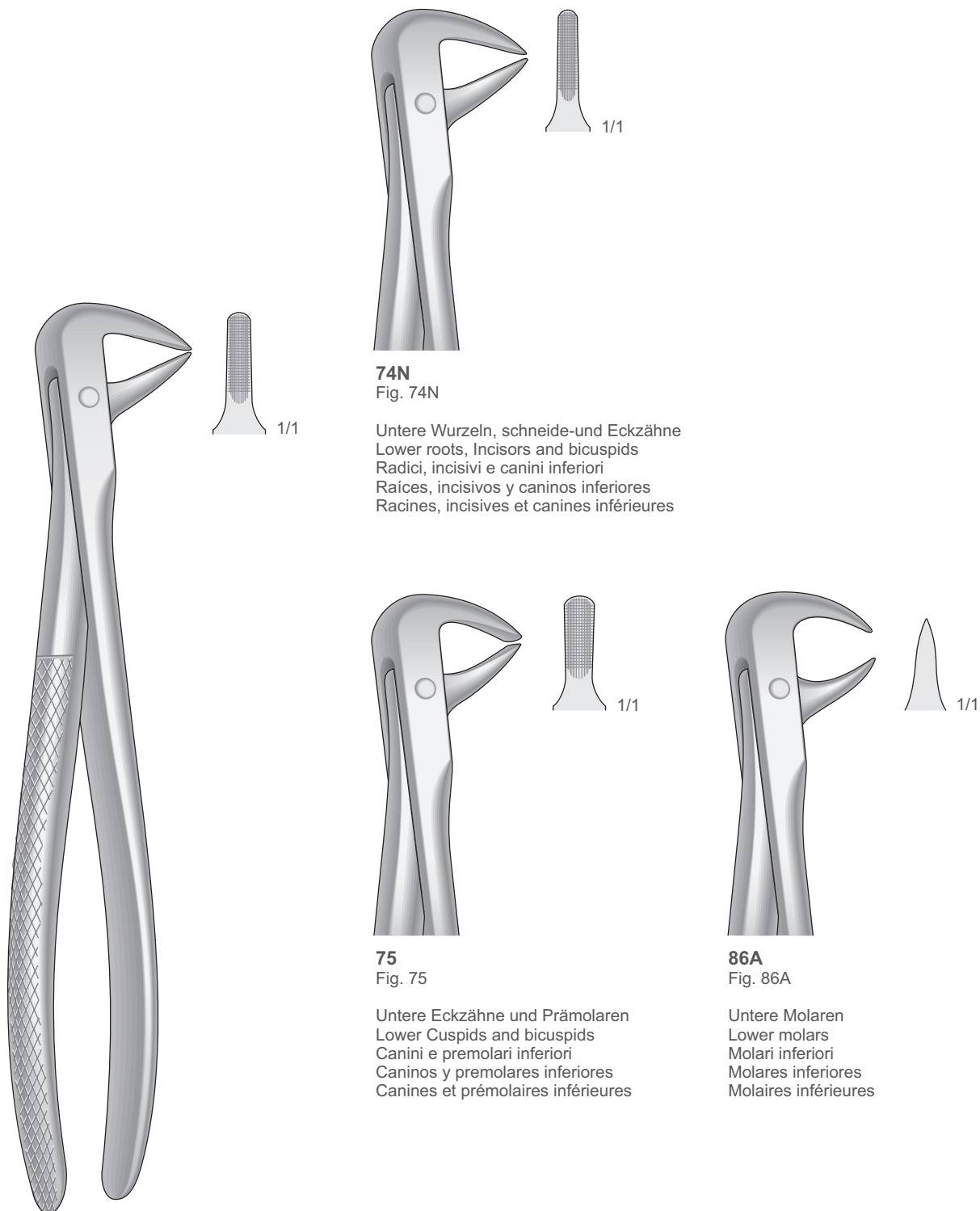
Untere Molaren  
 Lower molars  
 Molari inferiori  
 Molares inferiores  
 Molaires inférieures

## Extracting Forceps, English Pattern

Zahnzangen, Englische Form  
Pinze per estrazione, Forma Inglese  
Pinzas da extracci6n, Forma Inglesa  
Daviers, Forme Anglaise

## Forceps

Pinzetten  
Pinzas  
Pinces  
Pinzei



**74N**  
Fig. 74N

Untere Wurzeln, schneide-und Eckzähne  
Lower roots, Incisors and bicuspid  
Radici, incisivi e canini inferiori  
Raíces, incisivos y caninos inferiores  
Racines, incisives et canines inférieures

**75**  
Fig. 75

Untere Eckzähne und Prämolaren  
Lower Cuspid and bicuspid  
Canini e premolari inferiori  
Caninos y premolares inferiores  
Canines et prémolaires inférieures

**86A**  
Fig. 86A

Untere Molaren  
Lower molars  
Molari inferiori  
Molares inferiores  
Molaires inférieures

**74**  
Fig. 74  
Untere Wurzeln  
Lower roots  
Radici inferiori  
Raíces inferiores  
Racines inférieures

## Extracting Forceps, English Pattern

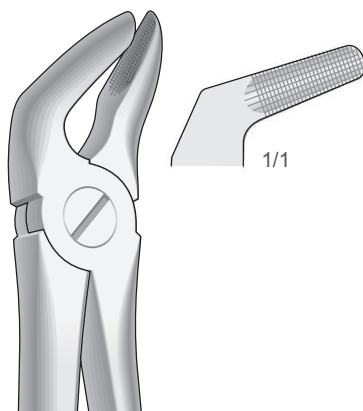
Zahnzangen, Englische Form  
 Pinze per estrazione, Forma Inglese  
 Pinzas da extracción, Forma Inglesa  
 Daviers, Forme Anglaise



**4**

Fig. 4

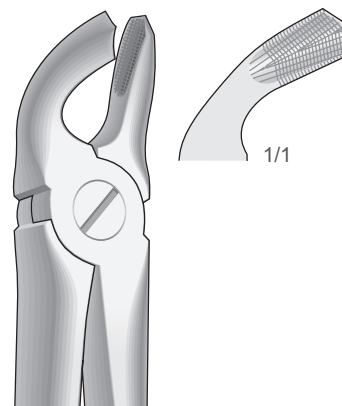
Untere Schneide- und Eckzähne  
 Lower Incisors and cuspids  
 Incisivi e canini inferiori  
 Incisivos y caninos inferiores  
 Incisives et canines inférieures



**8**

Fig. 8

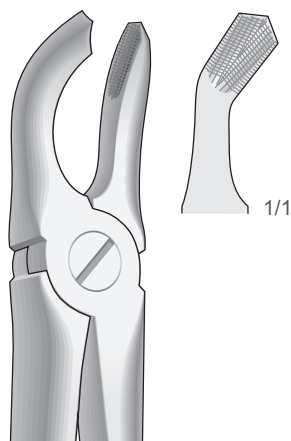
Untere Prämolaren  
 Lower premolars  
 Premolari inferiori  
 Premolares inferiores  
 Prémolaires inférieures



**21**

Fig. 21

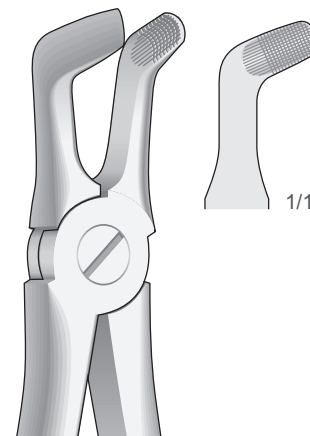
Untere Weisheitszähne und Molaren  
 Lower wisdom teeth and molars  
 Denti del giudizio e molari inferiori  
 Muelas del juicio y Molares inferiores  
 Dents de sagesse et molaires inférieures



**79**

Fig. 79

Untere Weisheitszähne  
 Lower wisdom teeth  
 Denti del giudizio inferiori  
 Muelas del juicio inferiores  
 Dent de sagesse inférieures



**79A**

Fig. 79A

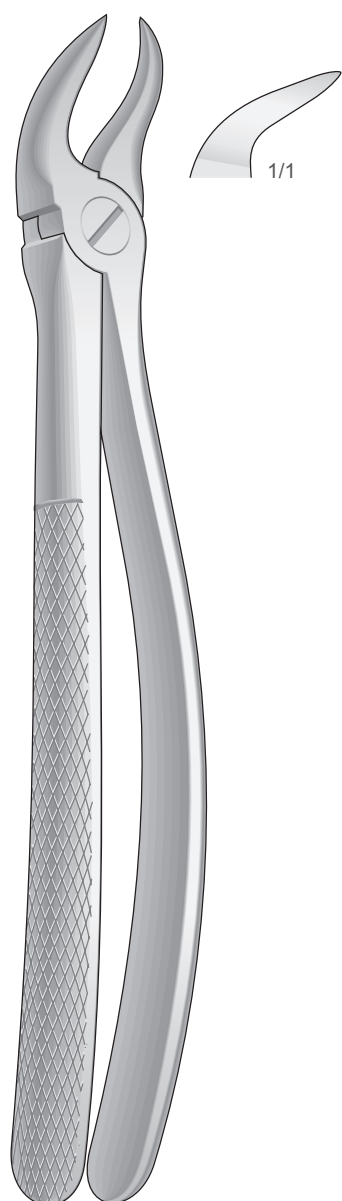
Untere Molaren und Weisheitszähne  
 Lower molars and wisdom teeth  
 Molari e denti del giudizio inferiori  
 Molares y muelas del juicio inferiores  
 Molaires et dent de sagesse inférieures

## Extracting Forceps, English Pattern

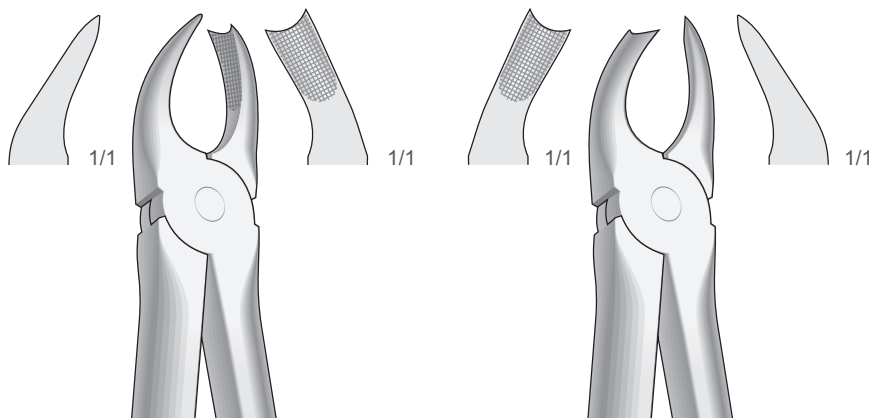
Zahnzangen, Englische Form  
 Pinze per estrazione, Forma Inglese  
 Pinzas da extracci6n, Forma Inglesa  
 Daviers, Forme Anglaise

## Forceps

Pinzetten  
 Pinzas  
 Pinces  
 Pinzei

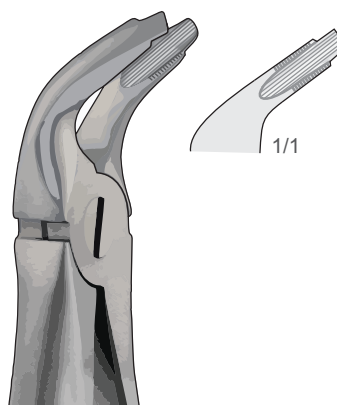


**87**  
 Fig. 87  
 Untere Molaren  
 Lower molars  
 Molari inferiori  
 Molares inferiores  
 Molaires inférieures



**89**  
 Fig. 89  
 Obere Molaren, rechts  
 Upper molars, right  
 Molari superiori, destra  
 Molares superiores, derechos  
 Molaires supérieures, droites

**90**  
 Fig. 90  
 Obere Molaren, links  
 Upper molars, left  
 Molari superiori, sinistra  
 Molares superiores, izquierdos  
 Molaires supérieures, gauches



**AM-451**  
 Fig. 451  
 Deep Grip

Untere Wurzeln, schneide-und Eckzähne  
 Lower roots, incisors and bicuspid  
 Radici, incisivi e canini inferiori  
 Raíces, incisivos y caninos inferiores  
 Racines, incisives et canines inférieures



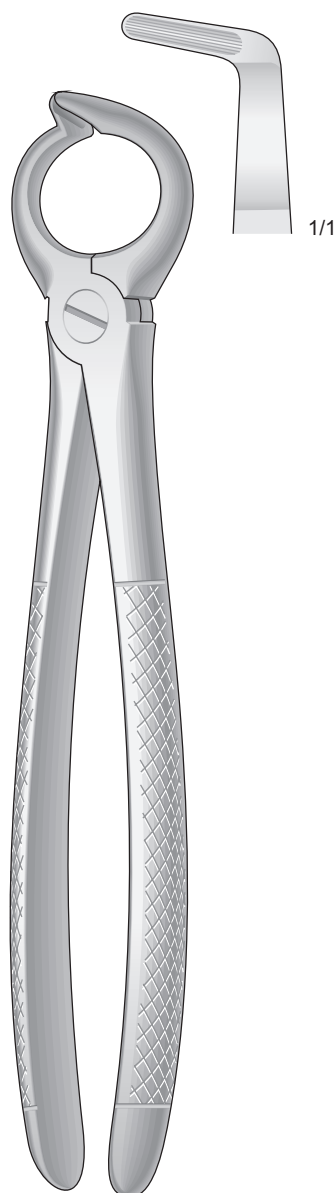
## Extracting Forceps, English Pattern

Zahnzangen, Englische Form

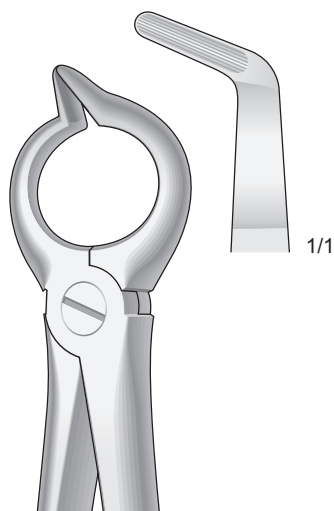
Pinze per estrazione, Forma Inglese

Pinzas da extracci6n, Forma Inglesa

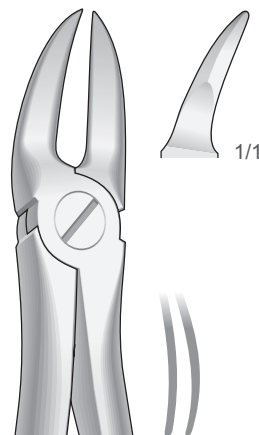
Daviers, Forme Anglaise



**68**  
Fig. 68  
Untere Wurzeln  
Lower Roots  
Radici inferiori  
Raices inferiores  
Racines inférieures

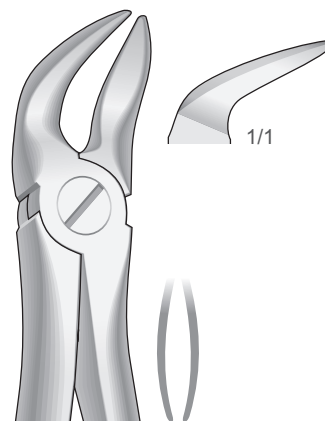


**68A**  
Fig. 68A  
Untere Wurzeln  
Lower Roots  
Radici inferiori  
Raices inferiores  
Racines inférieures



**55**  
Fig. 55

Zum Trennen oberer Molarenwurzeln  
For separating upper molar roots  
Per radici dei molari superiori, presa in profondit   
Para partir raices de molares superiores, profundo  
Pour s parer les racines des molaires sup rieures



**56**  
Fig. 56

Zum Trennen Unterer Molarenwurzeln  
For separating lower molar roots  
Per radici dei molari inferiori, presa in profondit   
Para partir raices de molares inferiores, profundo  
Pour s parer les racines des molaires inf rieures

## Extracting Forceps, English Pattern

Zahnzangen, Englische Form

Pinze per estrazione, Forma Inglese

Pinzas da extracci6n, Forma Inglesa

Daviers, Forme Anglaise

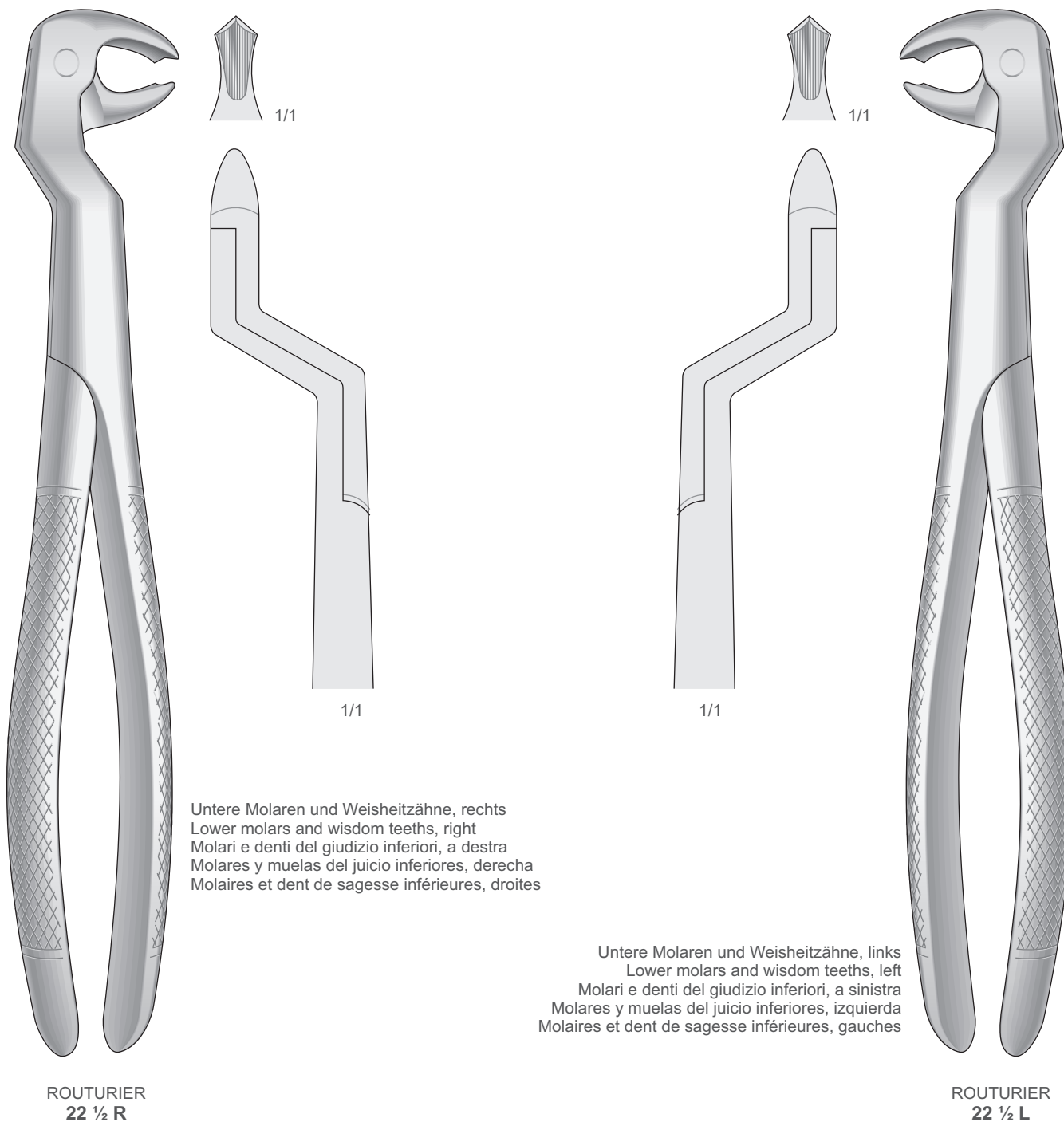
## Forceps

Pinzette

Pinzas

Pinces

Pinzei



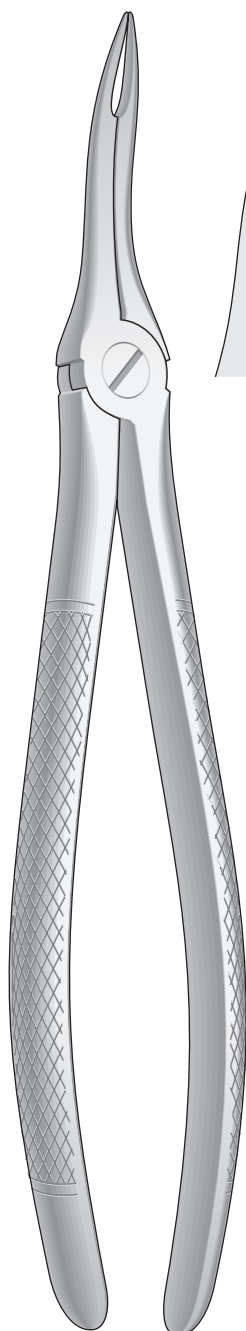
## Extracting Forceps, English Pattern

Zahnzangen, Englische Form

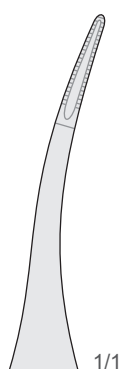
Pinze per estrazione, Forma Inglese

Pinzas da extracci6n, Forma Inglesa

Daviers, Forme Anglaise



**49**  
Fig. 49

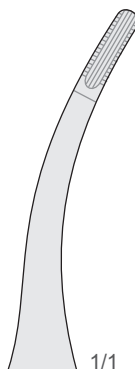


1/1

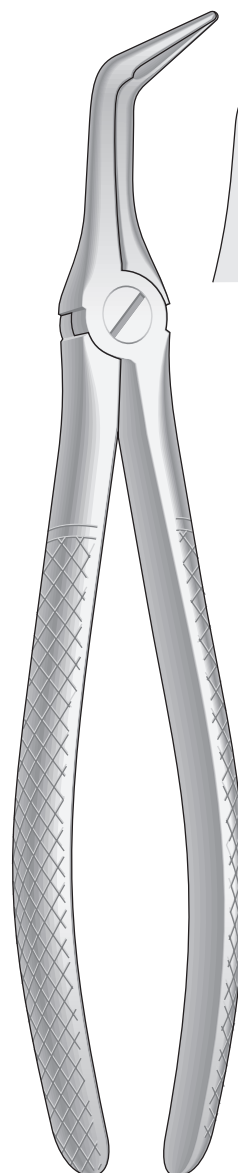


**48**  
Fig. 48 - 44

Obere Wurzeln  
Upper roots  
Radici superiori  
Raíces superiores  
Racines supérieures

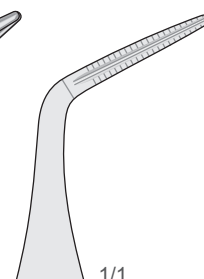


1/1



**46L**  
Fig. 46L

Untere Wurzeln  
Lower roots  
Radici inferiori  
Raíces inferiores  
Racines inférieures



1/1

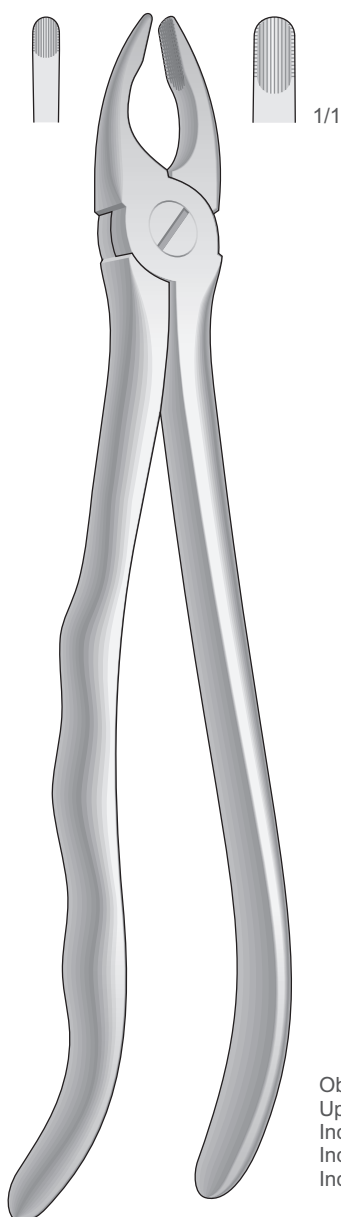
Obere Wurzeln sehr feine  
Upper very fine roots  
Radici superiori molto sottili  
Raíces superiores muy finas  
Racines supérieures très fines

## Extracting Forceps, Anatomical Handle

Zahnzangen, Paßformgriff  
 Pinze per estrazione, Manico anatomico  
 Pinzas da extracción, Mango anatómico  
 Daviers, Manche anatomique

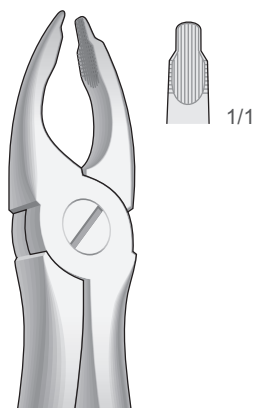
## Forceps

Pinzette  
 Pinzas  
 Pincers  
 Pinzei



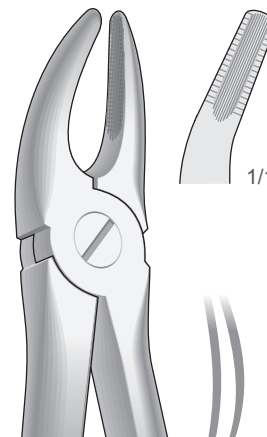
**S-3AN**  
 Fig. 3

Obere Schneide- und Eckzähne  
 Upper incisors and cuspids  
 Incisivi e canini superiori  
 Incisivos y caninos superiores  
 Incisives et canines supérieures



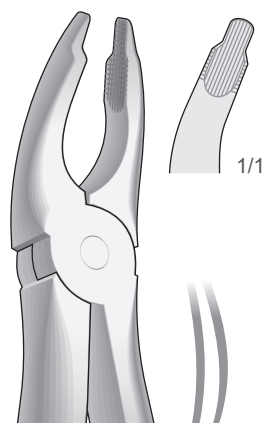
**S-34**  
 Fig. 34

Obere Schneide- und Eckzähne  
 Upper incisors and cuspids  
 Incisivi e canini superiori  
 Incisivos y caninos superiores  
 Incisives et canines supérieures



**S-7**  
 Fig. 7

Obere Prämolaren  
 Upper premolars  
 Premolari superiori  
 Premolares superiores  
 Prémolaires supérieures



**S-35**  
 Fig. 35

Obere Schneidezähne und Prämolaren, tiefgreifend  
 Upper incisors and bicuspid, deep-gripping  
 Incisivi e premolari superiori, presa in profondità  
 Incisivos y premolares superiores, a gran calado  
 Incisives et prémolaires supérieures, à attaque profonde

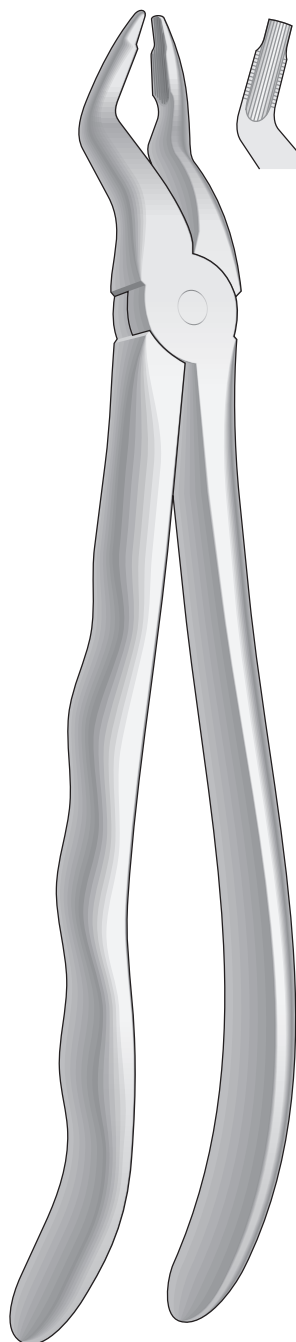
## Extracting Forceps, Anatomical Handle

Zahnzangen, Paßformgriff

Pinze per estrazione, Manico anatomico

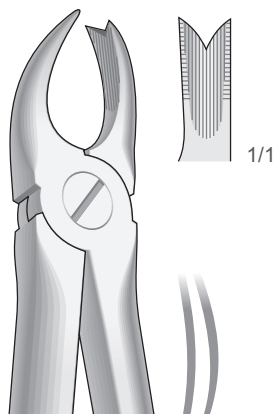
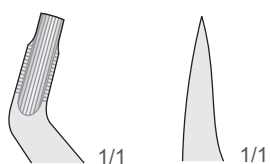
Pinzas da extracción, Mango anatómico

Daviers, Manche anatomique



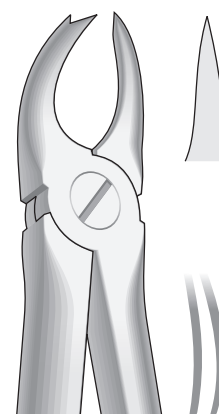
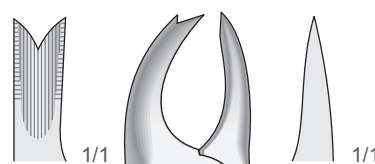
**S-31**  
Fig. 31

Obere Prämolaren  
Upper premolars  
Premolari superiori  
Premolares superiores  
Prémolaires supérieures



**S-66R**  
Fig. 66R (89)

Obere Molaren, rechts  
Upper molars, right  
Molari superiori, destra  
Molares superiores, derechos  
Molaires supérieures, droites



**S-66L**  
Fig. 66L (90)

Obere Molaren, links  
Upper molars, left  
Molari superiori, sinistra  
Molares superiores, izquierdos  
Molaires supérieures, gauches

## Extracting Forceps, Anatomical Handle

Zahnzangen, Paßformgriff

Pinze per estrazione, Manico anatomico

Pinzas da extracción, Mango anatómico

Daviers, Manche anatomique

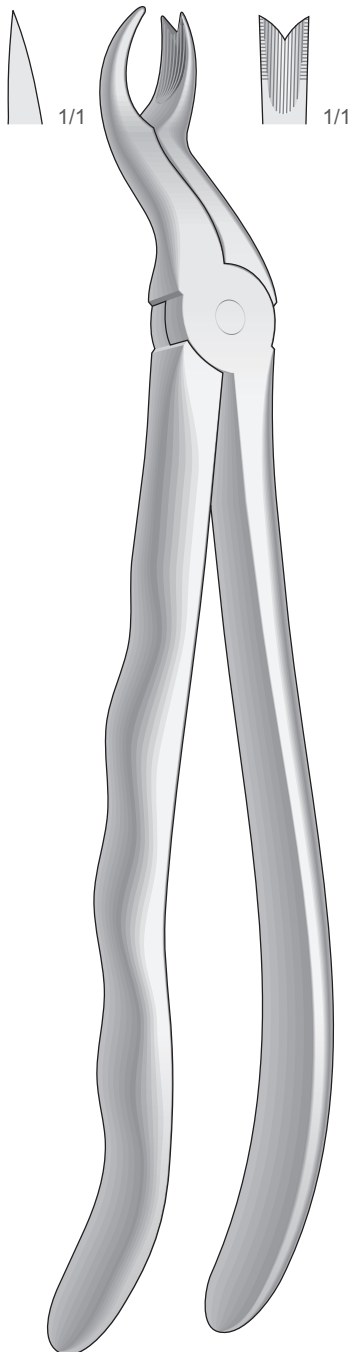
## Forceps

Pinzetten

Pinzas

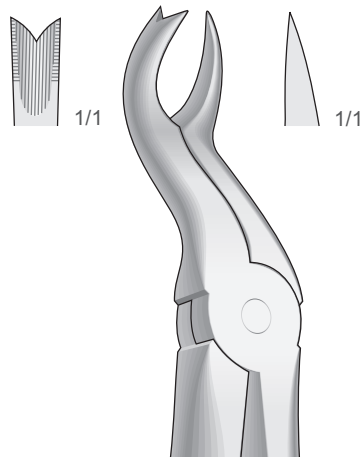
Pinces

Pinzei



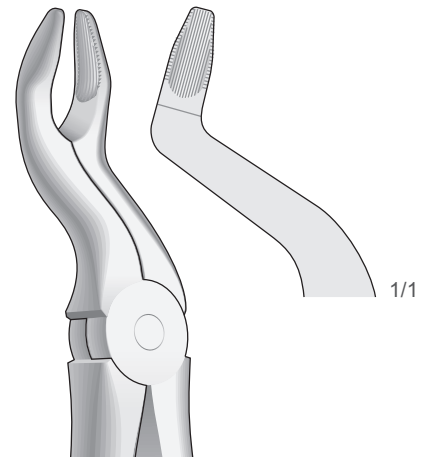
**S-67R**  
Fig. 67R

Obere Molaren, rechts  
Upper molars, right  
Molari superiori, destra  
Molares superiores, derechos  
Molaires supérieures, droites



**S-67L**  
Fig. 67L

Obere Molaren, links  
Upper molars, left  
Molari superiori, sinistra  
Molares superiores, izquierdos  
Molaires supérieures, gauches



**S-67N**  
Fig. 67N

Obere Molaren  
Upper molars  
Molari superiori  
Molares superiores  
Molaires supérieures

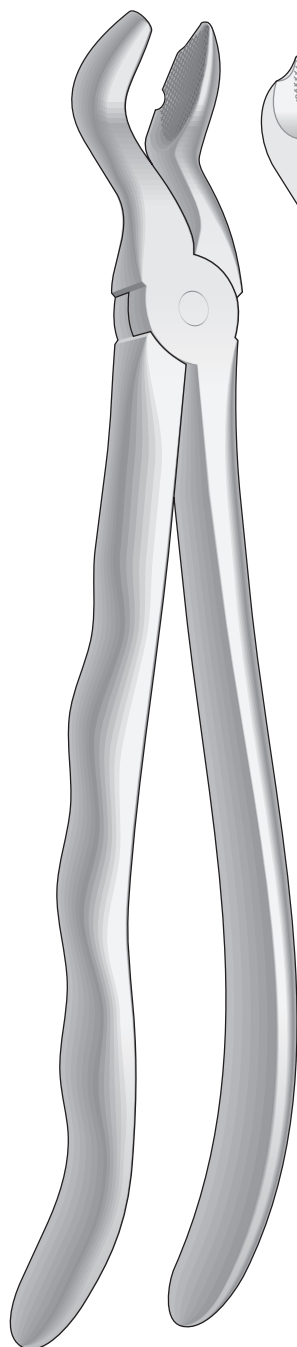
## Extracting Forceps, Anatomical Handle

Zahnzangen, Paßformgriff

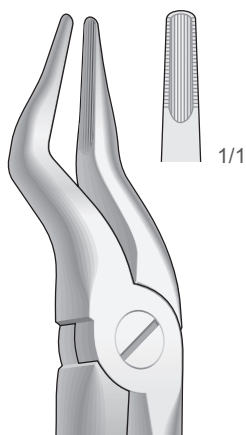
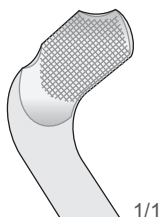Pinze per estrazione, Manico anatomico

Pinzas da extracción, Mango anatómico

Daviers, Manche anatomique

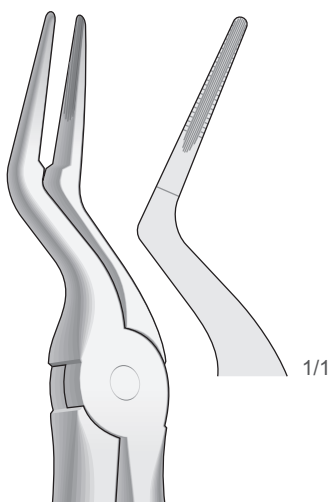


FELSCH  
**S-80**  
Fig. 80



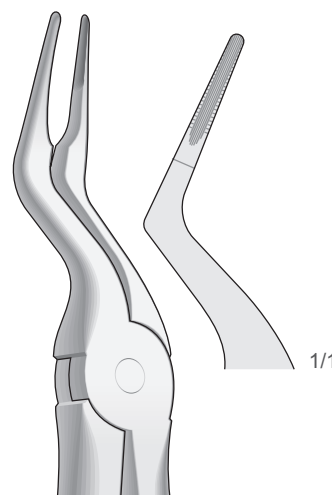
**S-51B**  
Fig. 51B

Obere Dritte Molaren  
Upper molars  
Ottavi superiori  
Molares superiores  
Molaires supérieures



**S-97**  
Fig. 97

Obere Wurzelplitterzange  
Upper Root Fragments  
Frammenti e radici superiori  
Fragmentos de raíces superiores  
Fragments des racines supérieures



**S-97B**  
Fig. 97B

Obere Wurzelplitterzange  
Upper Root Fragments  
Frammenti e radici superiori  
Fragmentos de raíces superiores  
Fragments des racines supérieures

Für obere Weisheitszähne, mit Fangvorrichtung  
For upper wisdom teeth, with retaining device  
Denti del giudizio superiori, con dispositivo di presa  
Muelas del juicio superiores, con dispositivo de retencion  
Pour dents de sagesse supérieures, mors conçus pour recueillir la dent

## Extracting Forceps, Anatomical Handle

Zahnzangen, Paßformgriff

Pinze per estrazione, Manico anatomico

Pinzas da extracción, Mango anatómico

Daviers, Manche anatomique

## Forceps

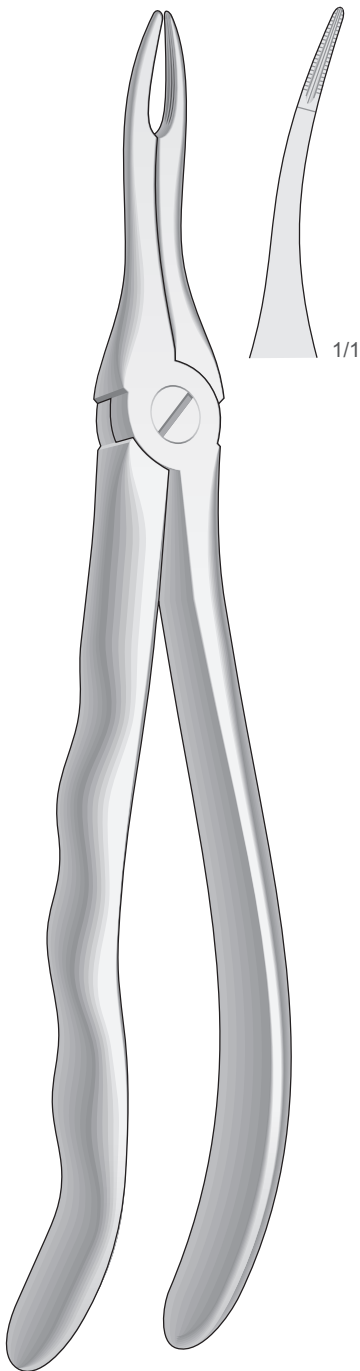
Pinzette

Pinzas

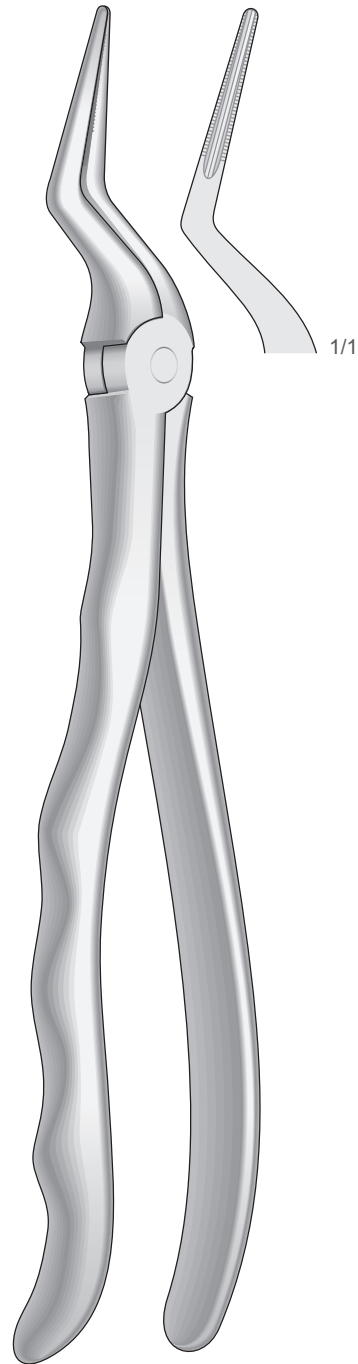
Pinces

Pinzei

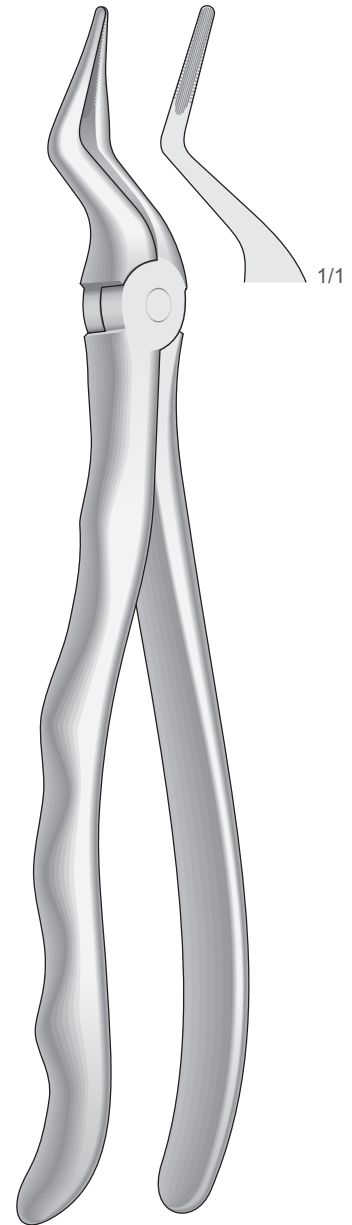
Obere Wurzeln sehr feine  
Upper very fine roots  
Radici superiori molto sottili  
Raíces superiores muy finas  
Racines supérieures très fines



**S-49**  
Fig. 49



**S-51LX**  
Fig. 51LX

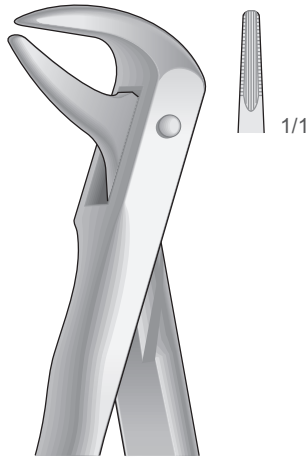


**S-351S**  
Fig. 351S



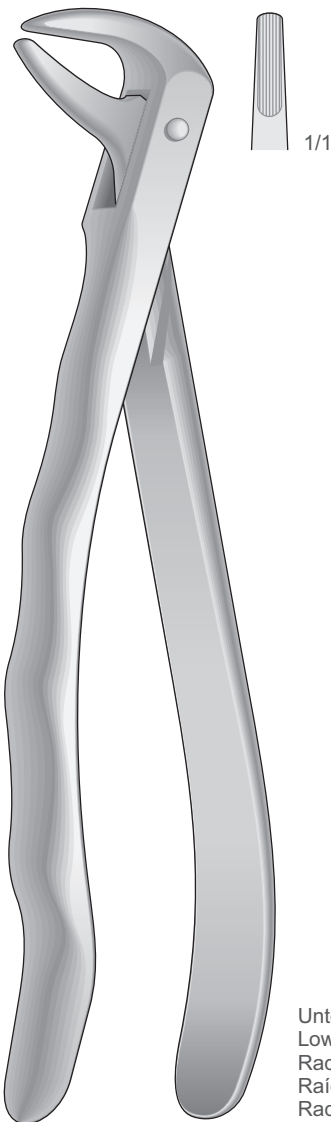
**Extracting Forceps, Anatomical Handle**

Zahnzangen, Paßformgriff  
 Pinze per estrazione, Manico anatomico  
 Pinzas da extracción, Mango anatómico  
 Daviers, Manche anatomique

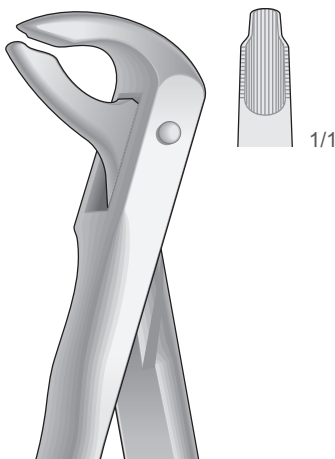


**I-74N**  
 Fig. 74N

Untere Wurzeln Schneide- und Eckzähne  
 Lower roots, incisors and cuspids  
 Radici, incisivi e canini inferiori  
 Raíces, incisivos y caninos inferiores  
 Racines, incisives et canines inférieures

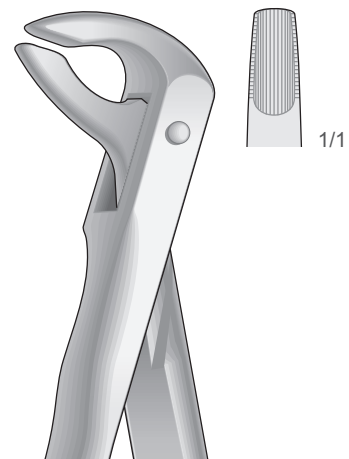


**I-74**  
 Fig. 74



**I-36**  
 Fig. 36

Untere Wurzeln Schneide- und Eckzähne  
 Lower roots, incisors and cuspids  
 Radici, incisivi e canini inferiori  
 Raíces, incisivos y caninos inferiores  
 Racines, incisives et canines inférieures



**I-36N**  
 Fig. 36N

Untere Wurzeln Schneide- und Eckzähne  
 Lower roots, incisors and cuspids  
 Radici, incisivi e canini inferiori  
 Raíces, incisivos y caninos inferiores  
 Racines, incisives et canines inférieures

Untere Wurzeln Schneide- und Eckzähne  
 Lower roots, incisors and cuspids  
 Radici, incisivi e canini inferiori  
 Raíces, incisivos y caninos inferiores  
 Racines, incisives et canines inférieures

## Extracting Forceps, Anatomical Handle

Zahnzangen, Paßformgriff  
 Pinze per estrazione, Manico anatomico  
 Pinzas da extracción, Mango anatómico  
 Daviers, Manche anatomique

## Forceps

Pinzette  
 Pinzas  
 Pincés  
 Pinzei



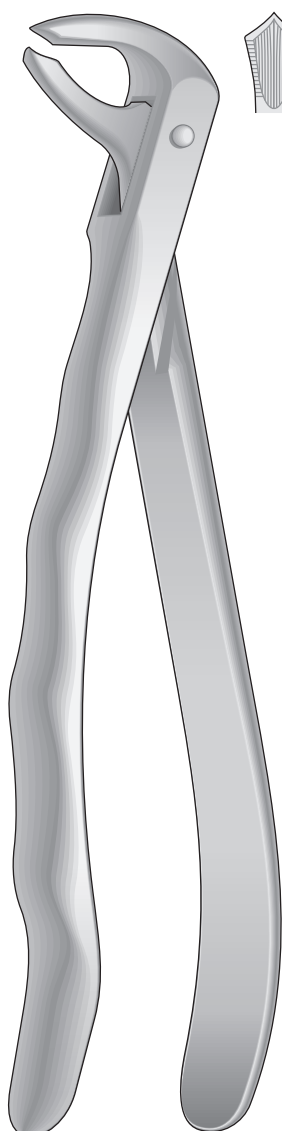
**I-59**  
 Fig. 59

Untere Wurzelplitterzange  
 Lower Root Fragments  
 Frammenti e radici inferiori  
 Fragmentos de raíces inferiores  
 Fragments des racines inférieures



**I-86C**  
 Fig. 86C

Untere Molaren mit kariesen oder abgebrochenen Kronen  
 Lower molars with carious or broken caps  
 Molari inferiori con corone cariate o spezzate  
 Molares inferiores con coronas rotas o cariadas  
 Molaires inférieures avec couronnes cariées ou cassées

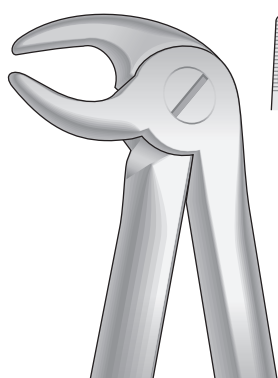


**I-73**  
 Fig. 73



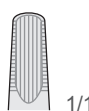
1/1

Untere Molaren  
 Lower molars  
 Molari inferiori  
 Molares inferiores  
 Molaires inférieures



**I-13**  
 Fig. 13

Untere Prämolaren und Eckzähne  
 Lower premolars and cuspids  
 Canini e premolari inferiori  
 Caninos y premolares inferiores  
 Canines et prémolaires inférieures

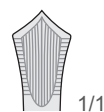


1/1



**I-22**  
 Fig. 22

Untere Molaren  
 Lower molars  
 Molari inferiori  
 Molares inferiores  
 Molaires inférieures



1/1

## Extracting Forceps, Anatomical Handle

Zahnzangen, Paßformgriff

Pinze per estrazione, Manico anatomico

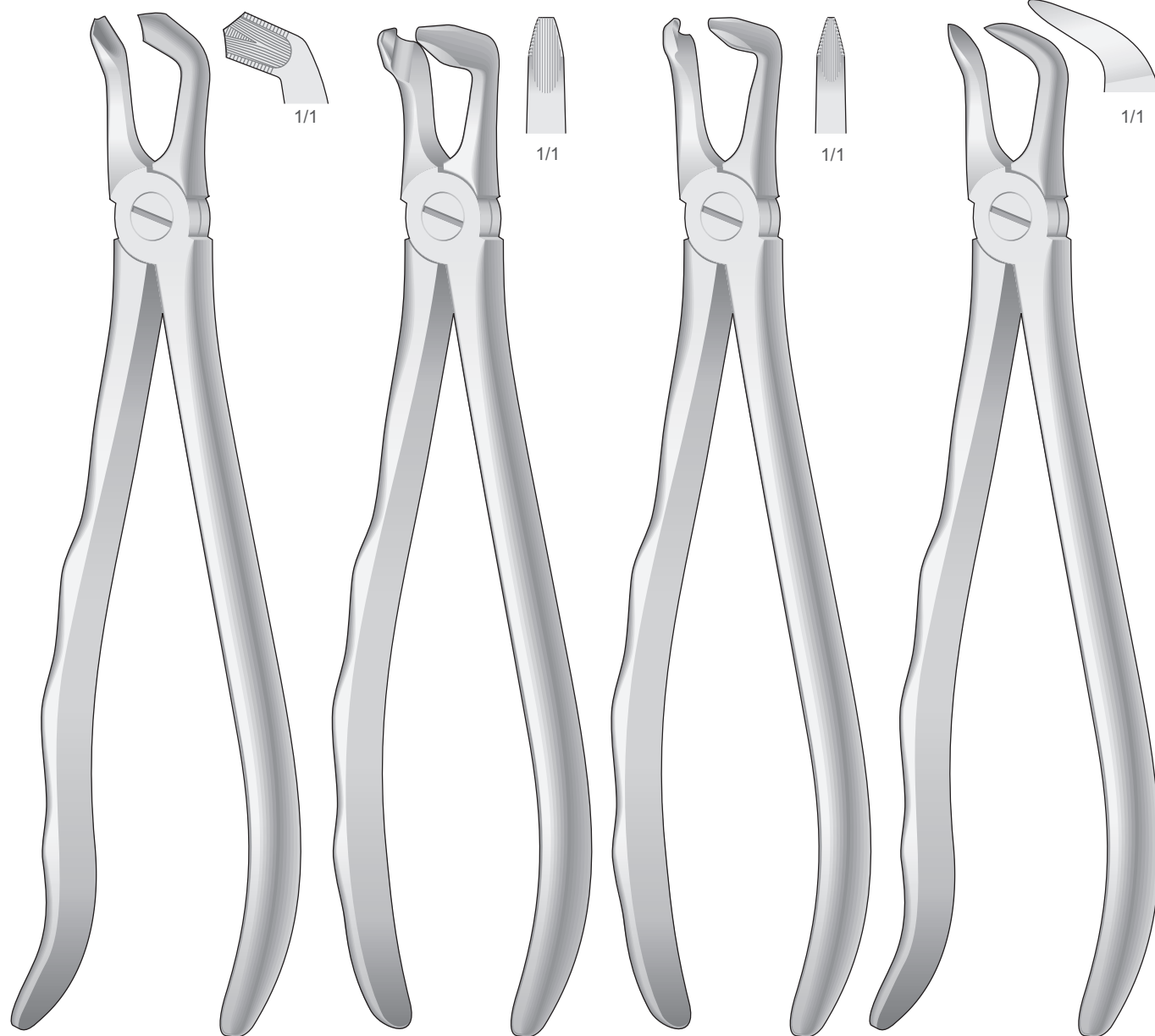Pinzas da extracción, Mango anatómico

Daviers, Manche anatomique

Untere Weisheitszähne  
Lower wisdom teeth  
Denti del giudizio inferiori  
Muelas del juicio inferiores  
Dent de sagesse inférieures

Untere Prämolaren  
Lower premolars  
Premolari inferiori  
Premolares inferiores  
Prémolaires inférieures

Untere Molaren  
Lower Molars  
Molari inferiori  
Molares inferiores  
Molaires inférieures



**I-79**  
Fig. 79

**I-79N**  
Fig. 79N

**I-46N**  
Fig. 46N

**I-87**  
Fig. 87

## Extracting Forceps, Anatomical Handle

Zahnzangen, Paßformgriff

Pinze per estrazione, Manico anatomico

Pinzas da extracción, Mango anatómico

Daviers, Manche anatomique

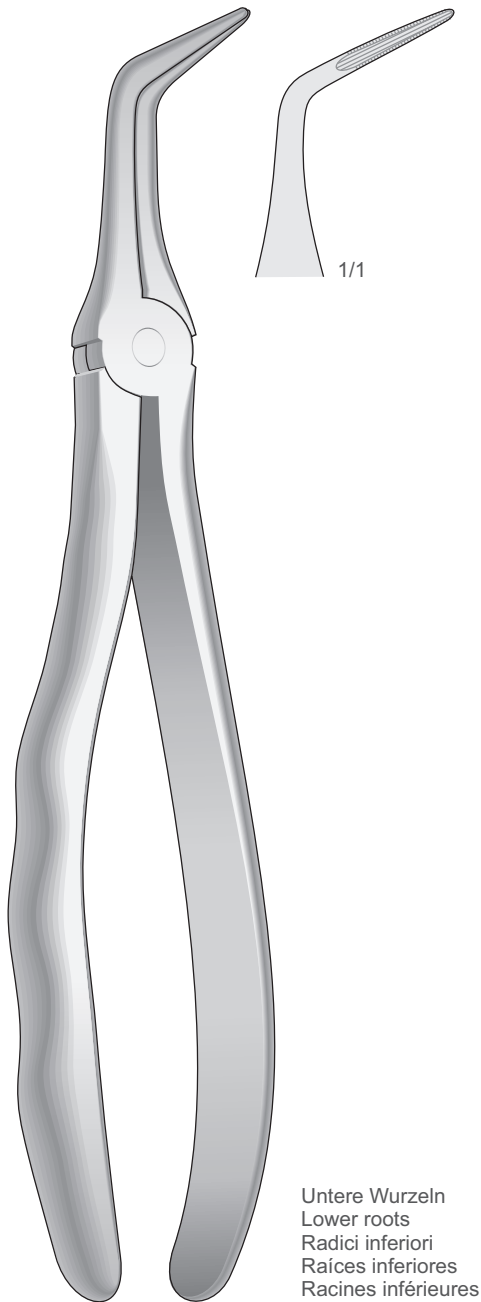## Forceps

Pinzetten

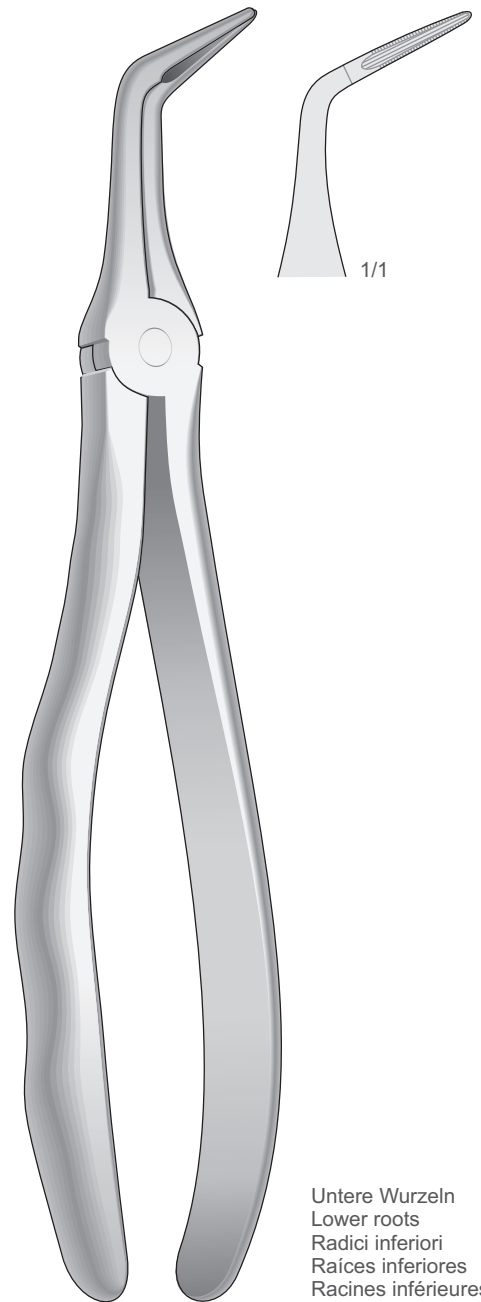Pinzas

Pinces

Pinzei



**I-46LX**  
Fig. 46LX



**I-46L**  
Fig. 46L

## Extracting Forceps, Anatomical Handle

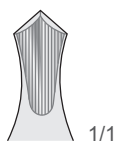
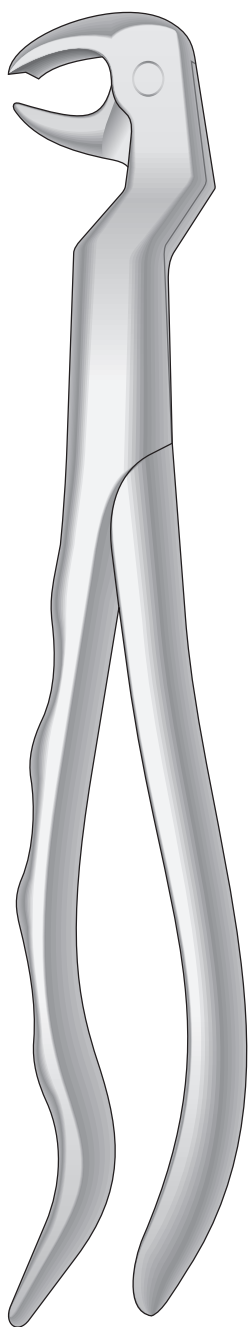
Zahnzangen, Paßformgriff

Pinze per estrazione, Manico anatomico

Pinzas da extracción, Mango anatómico

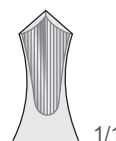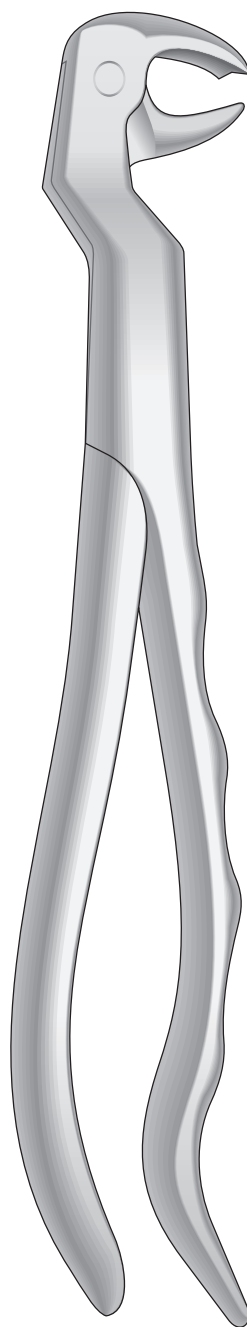
Daviers, Manche anatomique

Untere Molaren und Weisheitszähne  
Lower molars and wisdom teeth  
Molari e denti del giudizio inferiori  
Molares y muelas del juicio inferiores  
Molaires et dent de sagesse inférieures



Links  
Left  
Sinistra  
Izquierdos  
Gauches

I-22 1/2 L



Rechts  
Right  
Destra  
Derechos  
Droites

I-22 1/2 R

## Extracting Forceps, Anatomical Handle

Zahnzangen, Paßformgriff

Pinze per estrazione, Manico anatomico

Pinzas da extracción, Mango anatómico

Daviers, Manche anatomique

## Forceps

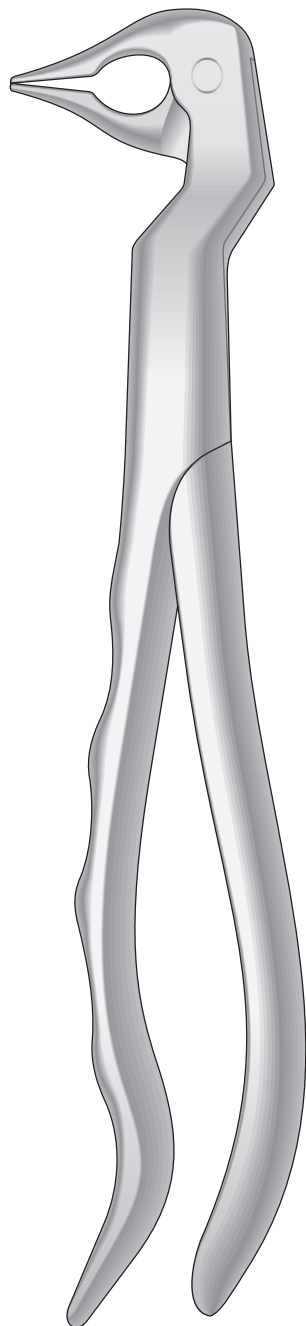
Pinzetten

Pinzas

Pinces

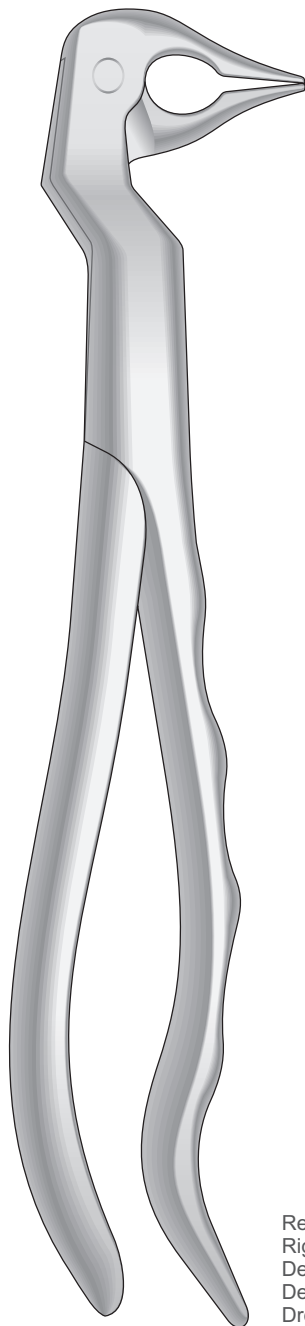
Pinzei

Untere Wurzeln sehr feine  
Lower very fine roots  
Radici inferiori molto sottili  
Raíces inferiores muy finas  
Racines inférieures très fines



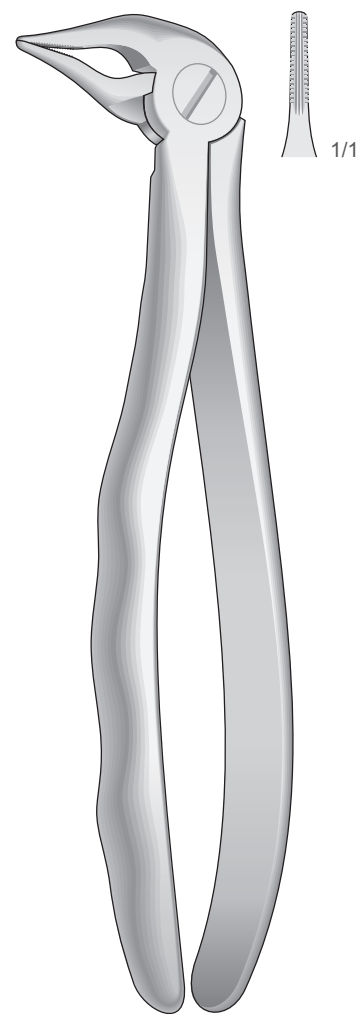
**I-133 L**  
Fig.133

Links  
Left  
Sinistra  
Izquierdos  
Gauches



**I-133 R**  
Fig.133

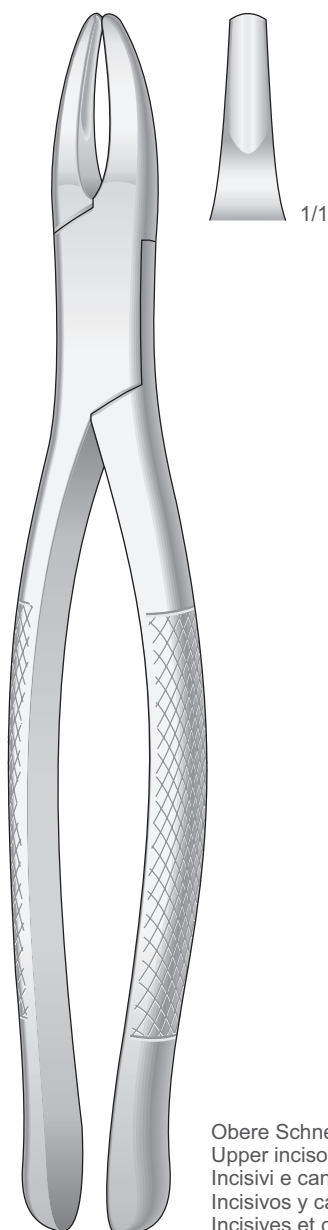
Rechts  
Right  
Dextra  
Derechos  
Droites



**I-333S**  
Fig.333S

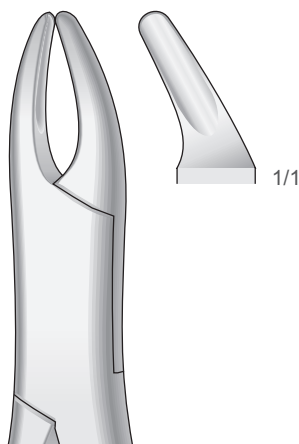
## Extracting Forceps, American Pattern

Zahnzangen, Amerikanische Form  
 Pinze per estrazione, Forma Americana  
 Pinzas da extracción, Forma Americana  
 Daviers, Forme Américaine



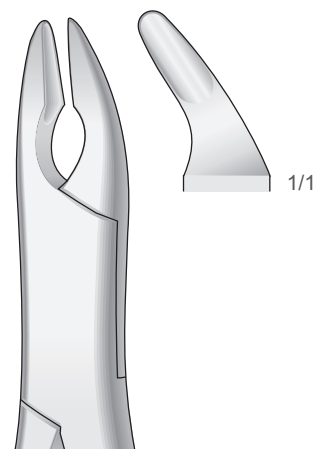
**AM-1**  
 Fig. 1

Obere Schneide- und Eckzähne  
 Upper incisors and cuspids  
 Incisivi e canini superiori  
 Incisivos y caninos superiores  
 Incisives et canines supérieures



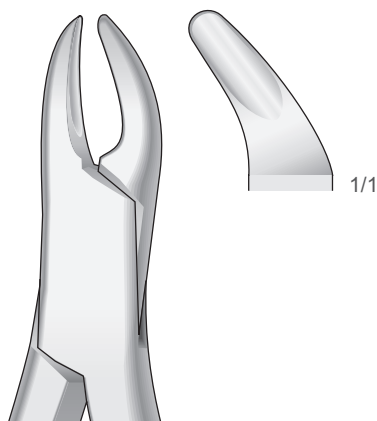
**CRYER**  
**AM-150**  
 Fig. 150

Obere Prämolaren, Schneidezähne, Wurzeln  
 Upper Bicuspid, incisors and roots  
 Premolari, incisivi e radici superiori  
 Premolares, incisivos y raíces superiores  
 Prémolaires, incisives et racines supérieures



**CRYER**  
**AM-150A**  
 Fig. 150A

Obere Prämolaren, Schneidezähne, Wurzeln  
 Upper Bicuspid, incisors and roots  
 Premolari, incisivi e radici superiori  
 Premolares, incisivos y raíces superiores  
 Prémolaires, incisives et racines supérieures



**AM-62**  
 Fig. 62

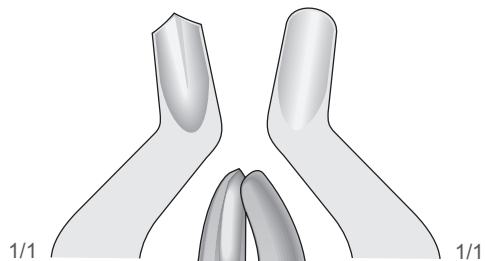
Schneidezähne, Prämolaren, Milchzähne  
 Incisors, premolars, deciduous teeth  
 Incisivi, premolari, denti da latte  
 Incisivos, premolares, dientes de leche  
 Incisives, prémolaires, dents de lait

## Extracting Forceps, American Pattern

Zahnzangen, Amerikanische Form  
 Pinze per estrazione, Forma Americana  
 Pinzas da extracción, Forma Americana  
 Daviers, Forme Américaine

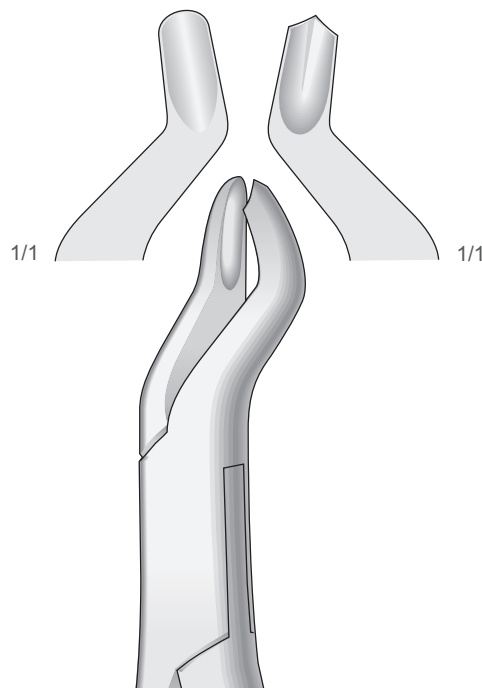
## Forceps

Pinzetten  
 Pinzas  
 Pincas  
 Pinzei



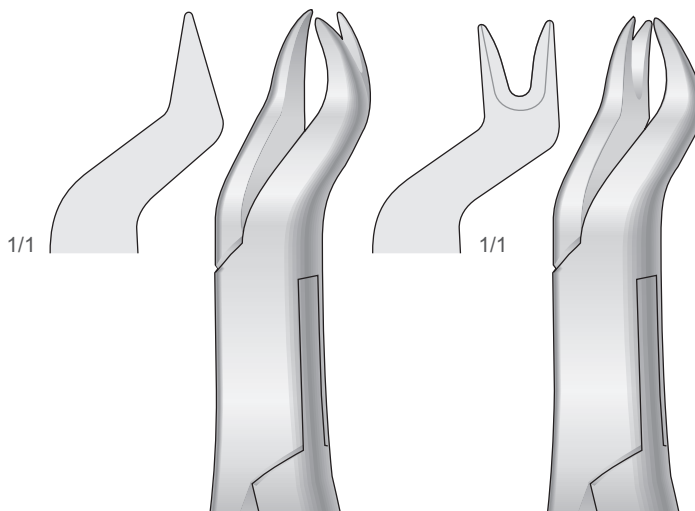
**AM-53R**  
 Fig. 53R

Obere Molaren, Rechts  
 Upper Molars, Right  
 Molari superiori, Destra  
 Molares superiores, Derechos  
 Molaires supérieures, Droites



**AM-53L**  
 Fig. 53L

Obere Molaren, Links  
 Upper Molars, Left  
 Molari superiori, Sinistra  
 Molares superiores, Izquierdos  
 Molaires supérieures, Gauches



NEVIUS  
**AM-88R**  
 Fig. 88R

Obere Molaren, Rechts  
 Upper Molars, Right  
 Molari superiori, Destra  
 Molares superiores, Derechos  
 Molaires supérieures, Droites

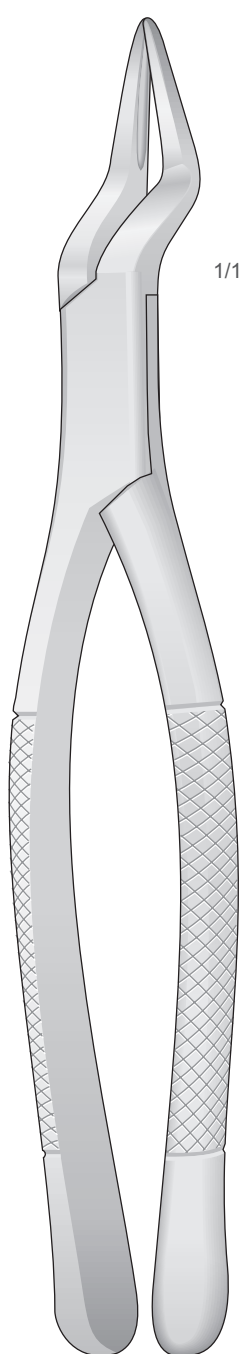
NEVIUS  
**AM-88L**  
 Fig. 88L

Obere Molaren, Links  
 Upper Molars, Left  
 Molari superiori, Sinistra  
 Molares superiores, Izquierdos  
 Molaires supérieures, Gauches



## Extracting Forceps, American Pattern

Zahnzangen, Amerikanische Form  
Pinze per estrazione, Forma Americana  
Pinzas da extracción, Forma Americana  
Daviers, Forme Américaine



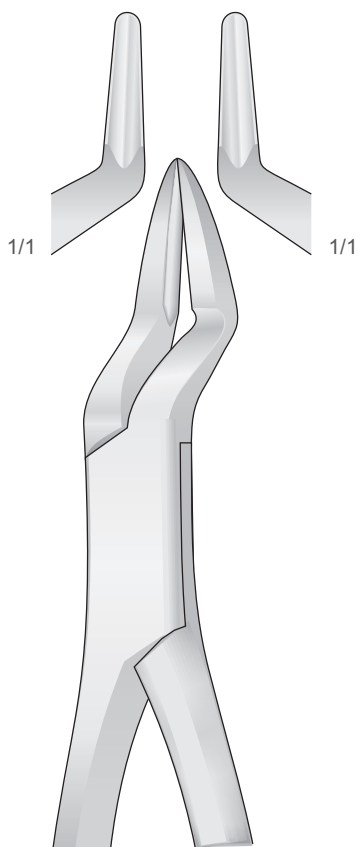
1/1



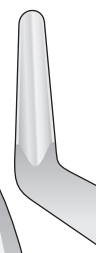
1/1

**AM-65**  
Fig.65

Obere Schneidezähne und Wurzeln  
Upper Incisors and Roots  
Incisivi e radici superiori  
Incisivos y raíces superiores  
Incisives et racines supérieures



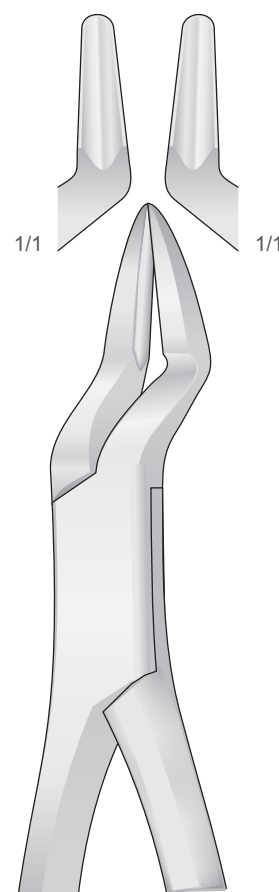
1/1



1/1

PARMLY  
**AM-32A**  
Fig. 32A

Obere Wurzeln und Prämolaren  
Upper Roots and Premolars  
Radici e premolari superiori  
Raíces y premolares superiores  
Racines et prémolaires supérieures



1/1



1/1

PARMLY  
**AM-32**  
Fig. 32

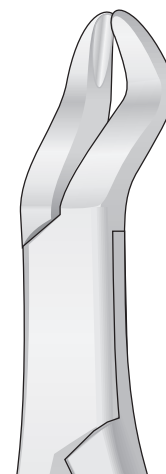
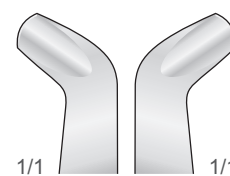
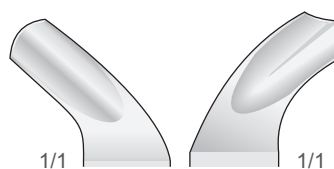
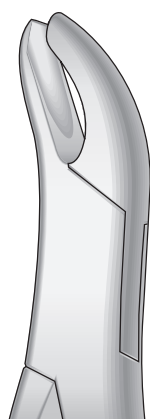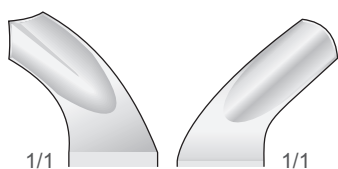
Obere Prämolaren und Molaren  
Upper Premolars and Molars  
Premolari e molari superiori  
Premolares y Molares superiores  
Prémolaires et Molaires supérieures

## Extracting Forceps, American Pattern

Zahnzangen, Amerikanische Form  
 Pinze per estrazione, Forma Americana  
 Pinzas da extracción, Forma Americana  
 Daviers, Forme Américaine

## Forceps

Pinzetten  
 Pinzas  
 Pincés  
 Pinzei



**AM-24**  
Fig. 24

Obere Molaren  
 Upper Molars  
 Molari superiori  
 Molares superiores  
 Molaires supérieures

HARRIS  
**AM-18R**  
Fig. 18R

Obere Molaren, Rechts  
 Upper Molars, Right  
 Molari superiori, Destra  
 Molares superiores, Derechos  
 Molaires supérieures, Droites

HARRIS  
**AM-18L**  
Fig. 18L

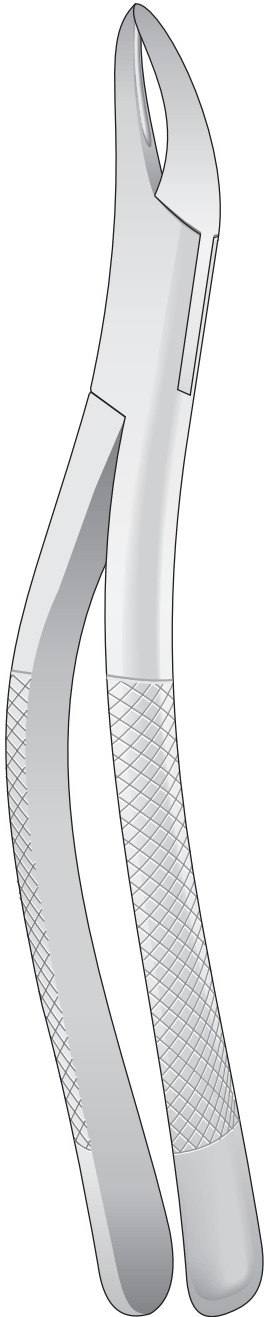
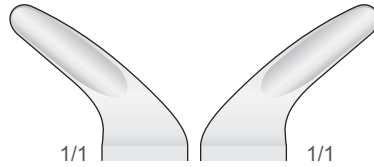
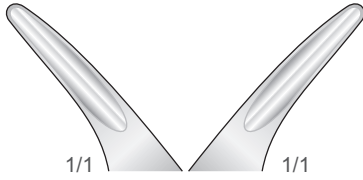
Obere Molaren, Links  
 Upper Molars, Left  
 Molari superiori, Sinistra  
 Molares superiores, Isquierdos  
 Molaires supérieures, Gauches

**AM-210**  
Fig. 210

Obere Molaren  
 Upper Molars  
 Molari superiori  
 Molares superiores  
 Molaires supérieures

**Extracting Forceps, American Pattern**

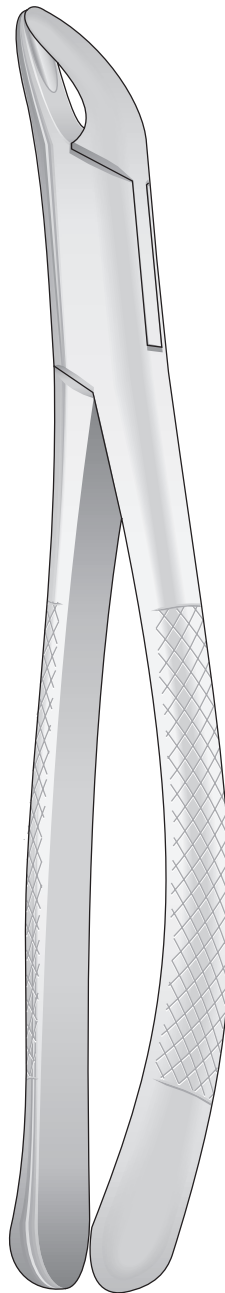
Zahnzangen, Amerikanische Form  
 Pinze per estrazione, Forma Americana  
 Pinzas da extracción, Forma Americana  
 Daviers, Forme Américaine



Obere und Untere  
 Upper and lower  
 Superiori e inferiori  
 Superiores y inferiores  
 Supérieures et inférieures

Wurzeln  
 Roots  
 Radici  
 Raíces  
 Racines

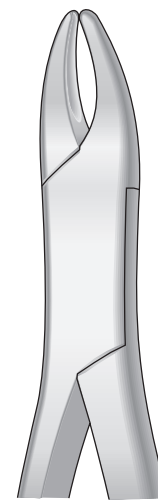**TOMEs**  
**AM-69**  
 Fig.69



Untere  
 Lower  
 Inferiori  
 Inferiores  
 Inférieures

Schneidezähne, Prämolaren, Wurzeln  
 Incisors, Premolars, Roots  
 Incisivi, premolari, radici  
 Incisivos, premolares, raíces  
 Incisives, prémolaires, racines

**CRYER**  
**AM-151**  
 Fig.151



**HULL**  
**AM-101**  
 Fig. 101

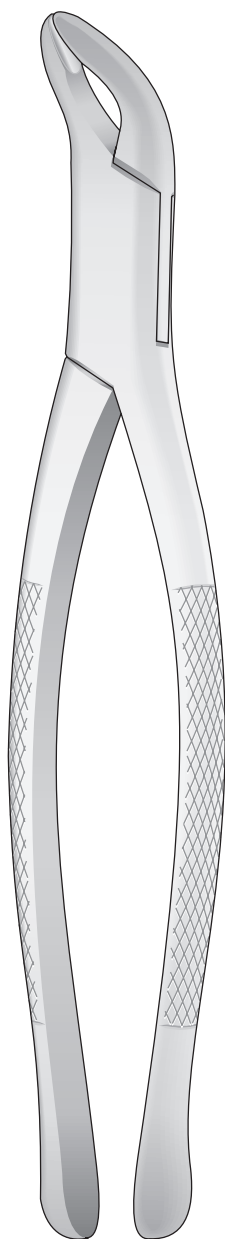
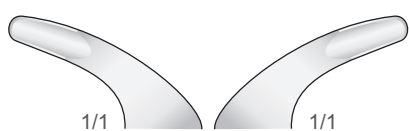
Für Eckzähne und Prämolaren,  
 Universalzange und Kinderzange  
 For canines and Premolars,  
 Universal and Tooth forceps for children  
 Canini e premolari,  
 universale e per bambini  
 Caninos y premolares,  
 universal y para niños  
 Canines et prémolaires,  
 universel et pour enfants

## Extracting Forceps, American Pattern

Zahnzangen, Amerikanische Form  
 Pinze per estrazione, Forma Americana  
 Pinzas da extracción, Forma Americana  
 Daviers, Forme Américaine

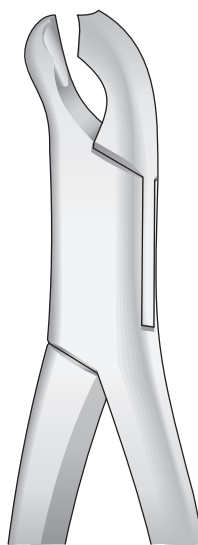
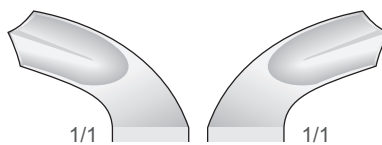
## Forceps

Pinzetten  
 Pinzas  
 Pinces  
 Pinzei



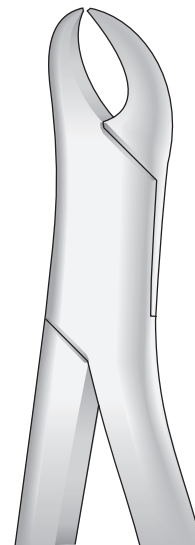
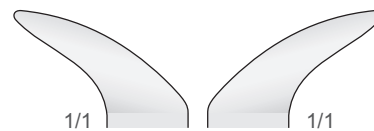
**AM-203**  
 Fig. 203

Untere Schneidezähne, Prämolaren, Wurzeln  
 Lower Incisors, Premolars, Roots  
 Incisivi, premolari, radici inferiori  
 Incisivos, premolares, raices inferiores  
 Incisives, prémolaires, racines inférieures



**AM-17**  
 Fig. 17

Untere Molaren  
 Lower Molars  
 Molari inferiori  
 Molares inferiores  
 Molaires inférieures

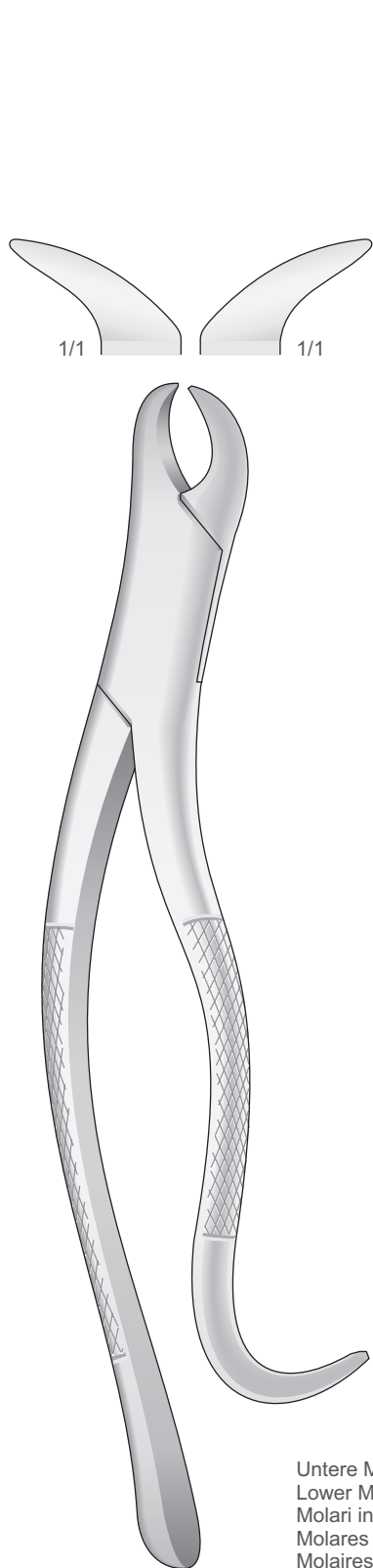


**AM-23**  
 Fig. 23

Untere Molaren  
 Lower Molars  
 Molari inferiori  
 Molares inferiores  
 Molaires inférieures

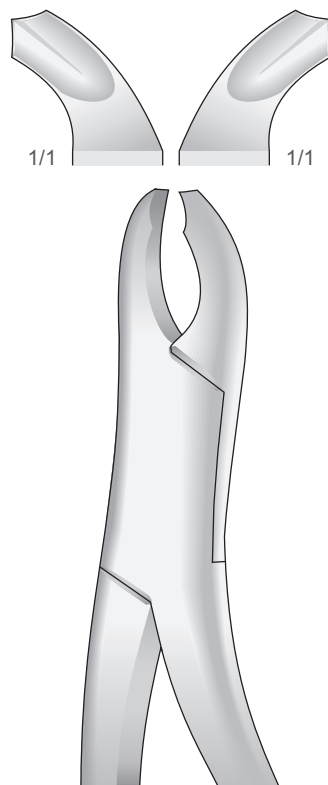
**Extracting Forceps, American Pattern**

Zahnzangen, Amerikanische Form  
 Pinze per estrazione, Forma Americana  
 Pinzas da extracción, Forma Americana  
 Daviers, Forme Américaine



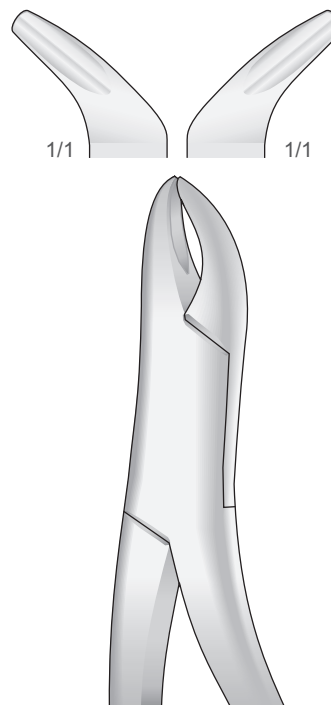
**AM-16**  
 Fig. 16

Untere Molaren  
 Lower Molars  
 Molari inferiori  
 Molares inferiores  
 Molaires inférieures



**HARRIS**  
**AM-15**  
 Fig. 15

Untere Molaren  
 Lower Molars  
 Molari inferiori  
 Molares inferiores  
 Molaires inférieures



**AM-103**  
 Fig. 103

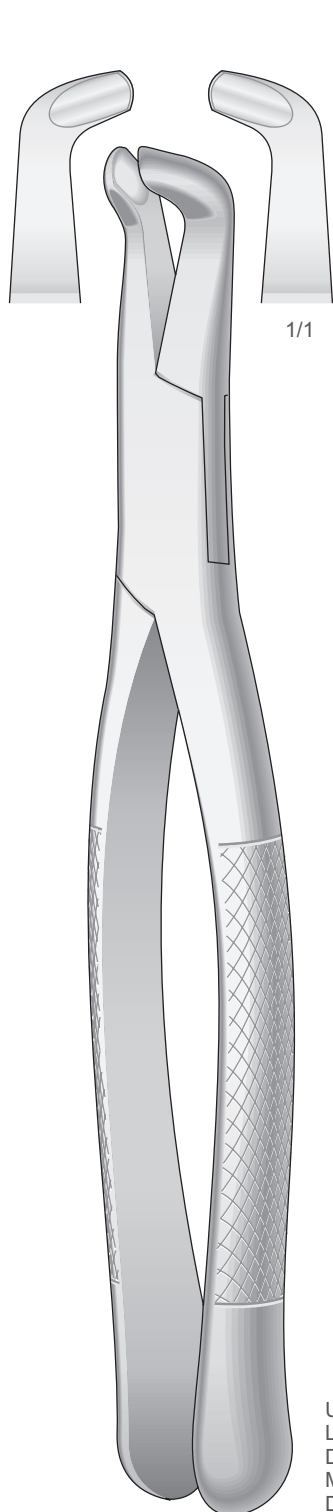
Untere Schneidezähne, Prämolaren, Wurzeln  
 Lower Incisors, Premolars, Roots  
 Incisivi, premolari, radici inferiori  
 Incisivos, premolares, raices inferiores  
 Incisives, prémolaires, racines inférieures

**Extracting Forceps, American Pattern**

Zahnzangen, Amerikanische Form  
 Pinze per estrazione, Forma Americana  
 Pinzas da extracción, Forma Americana  
 Daviers, Forme Américaine

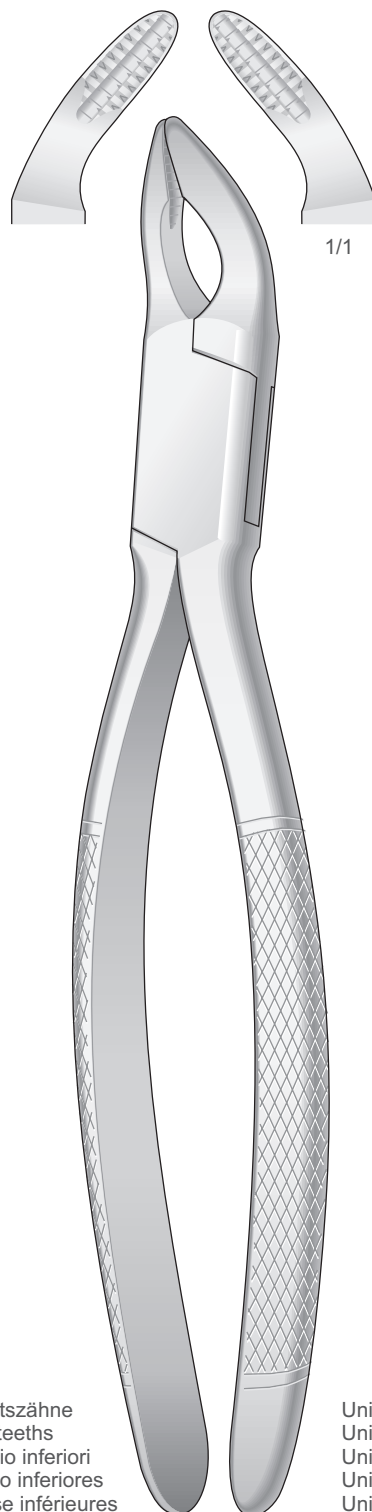
**Forceps**

Pinzetten  
 Pinzas  
 Pinces  
 Pinzei



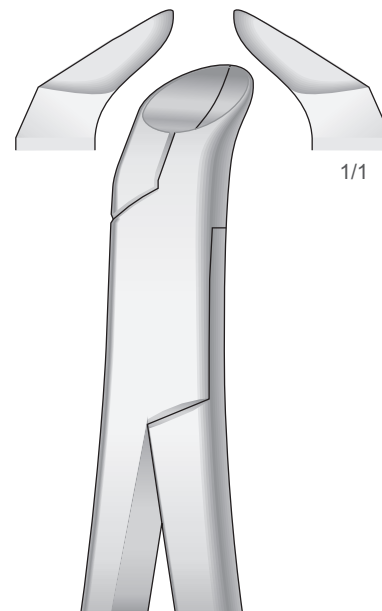
**AM-222**  
 Fig. 222

Untere Weisheitszähne  
 Lower wisdom teeth  
 Denti del giudizio inferiori  
 Muelas del juicio inferiores  
 Dent de sagesse inférieures



**COHEN**  
**AM-250**

Universal  
 Universal  
 Universale  
 Universal  
 Universel

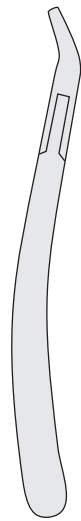
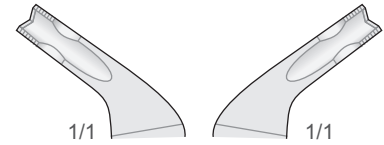
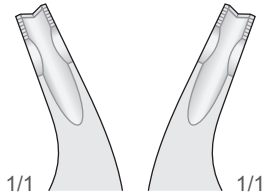


**PHYSICK**  
**AM-5**  
 Fig. 5

Untere Weisheitszähne  
 Lower wisdom teeth  
 Denti del giudizio inferiori  
 Muelas del juicio inferiores  
 Dent de sagesse inférieures

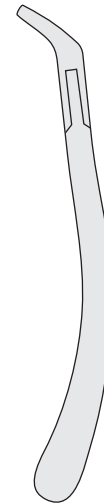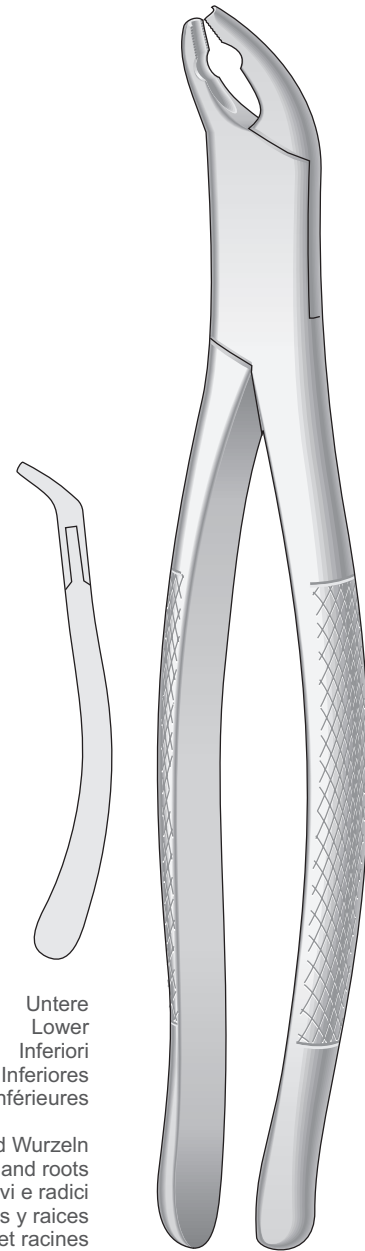
## Extracting Forceps, American Pattern

Zahnzangen, Amerikanische Form  
Pinze per estrazione, Forma Americana  
Pinzas da extracción, Forma Americana  
Daviers, Forme Américaine



Obere  
Upper  
Superiori  
Superiores  
Supérieures

Prämolaren, Schneidezähne und Wurzeln  
Bicuspids, incisors and roots  
Premolari, incisivi e radici  
Premolares, incisivos y raíces  
Premolaires, incisives et racines



Untere  
Lower  
Inferiori  
Inferiores  
Inférieures

Prämolaren, Schneidezähne und Wurzeln  
Bicuspids, incisors and roots  
Premolari, incisivi e radici  
Premolares, incisivos y raíces  
Premolaires, incisives et racines

**AM-150X**  
Fig. 150AS

**AM-151X**  
Fig. 151AS

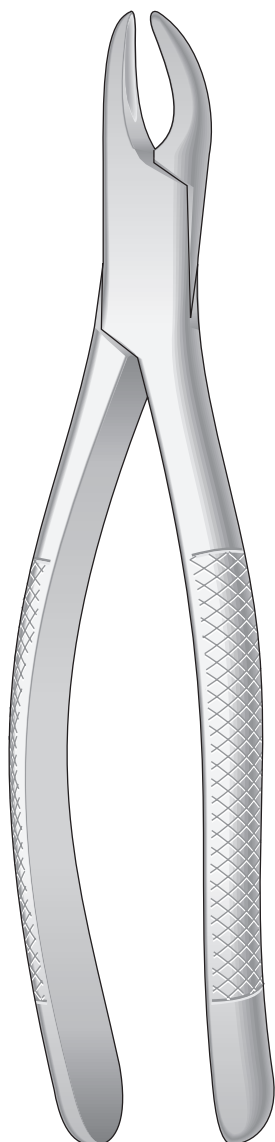
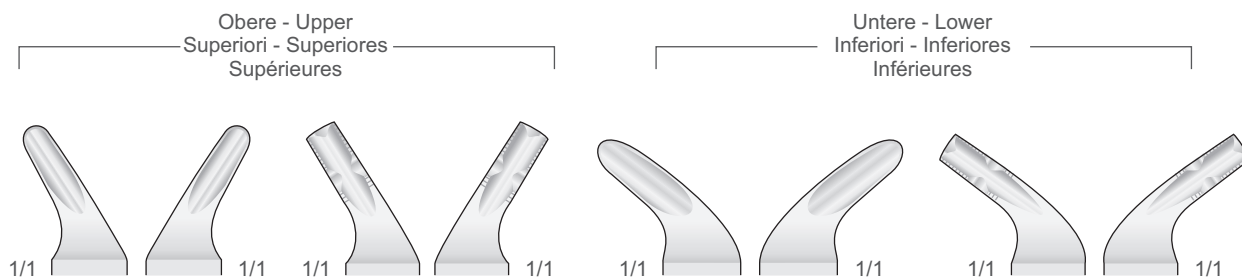
## Extracting Forceps, American Pattern

Zahnzangen, Amerikanische Form  
 Pinze per estrazione, Forma Americana  
 Pinzas da extracción, Forma Americana  
 Daviers, Forme Américaine

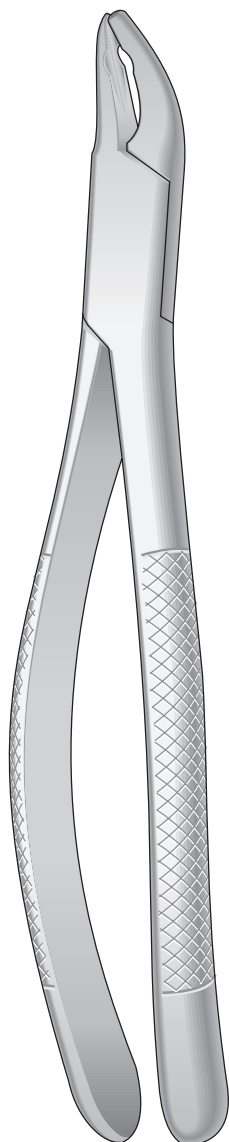
## Forceps

Pinzetten  
 Pinzas  
 Pincés  
 Pinzei

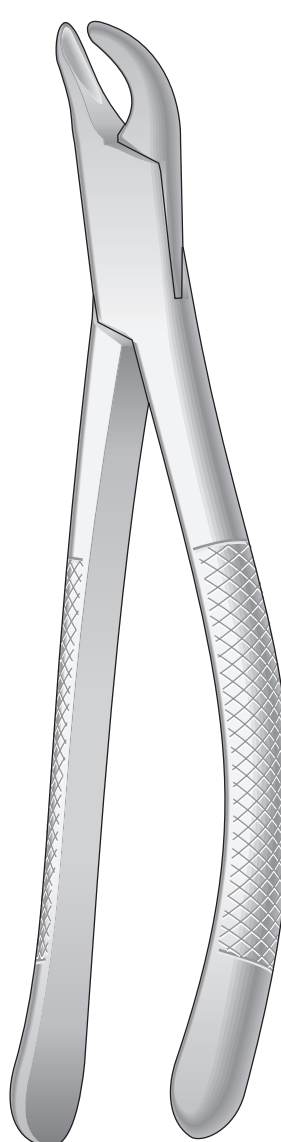
Für Kinder  
 For children  
 Per bambini  
 Para niños  
 Pour enfants



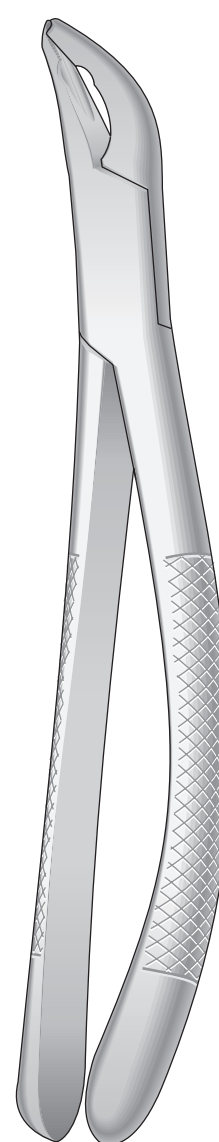
CRYER  
**AM-150S**  
 Fig.150 S



**AM-150AS**  
 Fig.150 XAS



CRYER  
**AM-151S**  
 Fig.151 S



**AM-151AS**  
 Fig.151 XAS



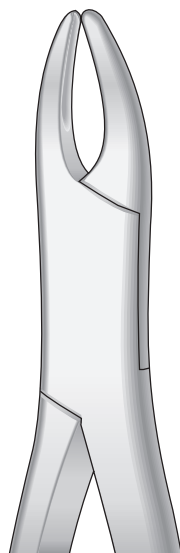
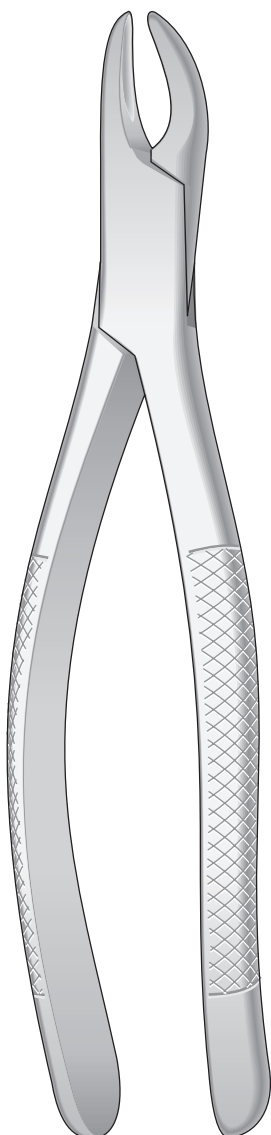
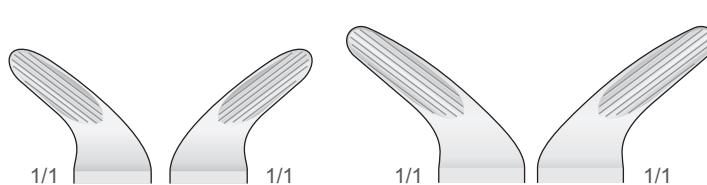
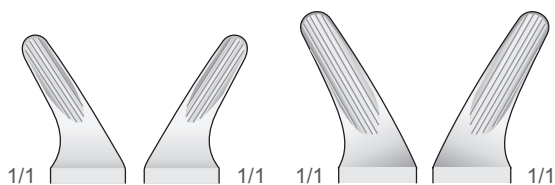
## Extracting Forceps, American Pattern

Zahnzangen, Amerikanische Form  
 Pinze per estrazione, Forma Americana  
 Pinzas da extracción, Forma Americana  
 Daviers, Forme Américaine

Geriefte - Serrated - Striata - Estriadas - Striées

Obere Schneidezähne, Prämolaren, Wurzeln  
 Upper incisors, premolars, roots  
 Incisivi, premolari e radici superiori  
 Incisivos, premolares y raíces superiores  
 Incisives, premolaires et racines supérieures

Untere Schneidezähne, Prämolaren, Wurzeln  
 Lower incisors, premolars, roots  
 Incisivi, premolari e radici inferiori  
 Incisivos, premolares y raíces inferiores  
 Incisives, premolaires et racines inférieures

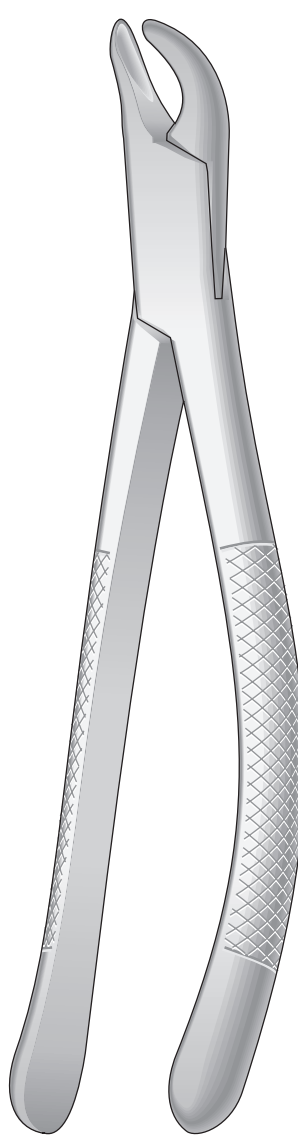


CRYER  
**AMG-150**  
 Fig. 150

Für Erwachsene  
 For adults  
 Per adulti  
 Para adultos  
 Pour adults

Für Kinder  
 For children  
 Per bambini  
 Para niños  
 Pour enfants

CRYER  
**AMG-150S**  
 Fig.150 S



CRYER  
**AMG-151**  
 Fig. 151

Für Erwachsene  
 For adults  
 Per adulti  
 Para adultos  
 Pour adults

Für Kinder  
 For children  
 Per bambini  
 Para niños  
 Pour enfants

CRYER  
**AMG-151S**  
 Fig.151 S

## Extracting Forceps

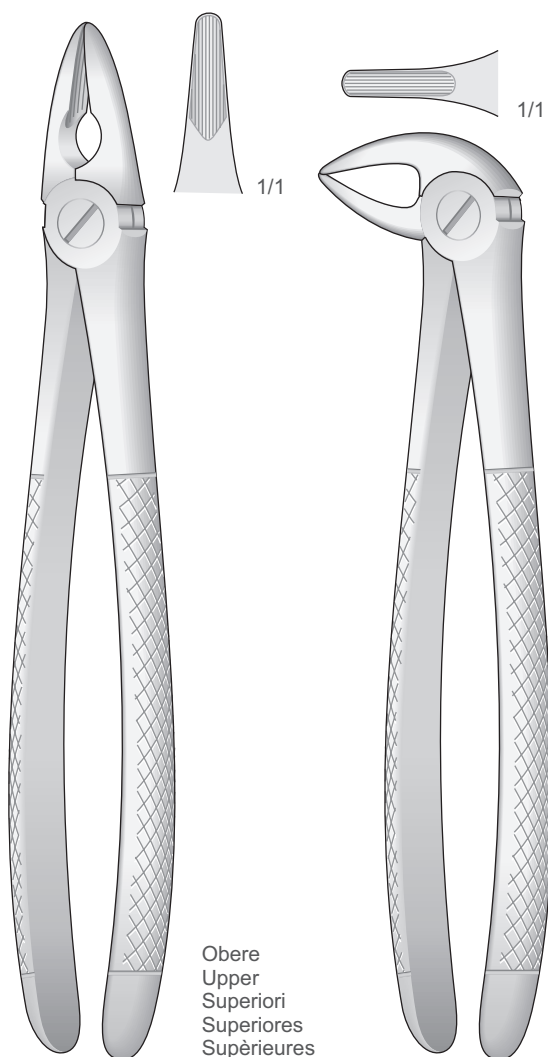
Zahnzangen  
Pinze per estrazione  
Pinzas da extracción  
Daviers

## Forceps

Pinzetten  
Pinzas  
Pinces  
Pinzei

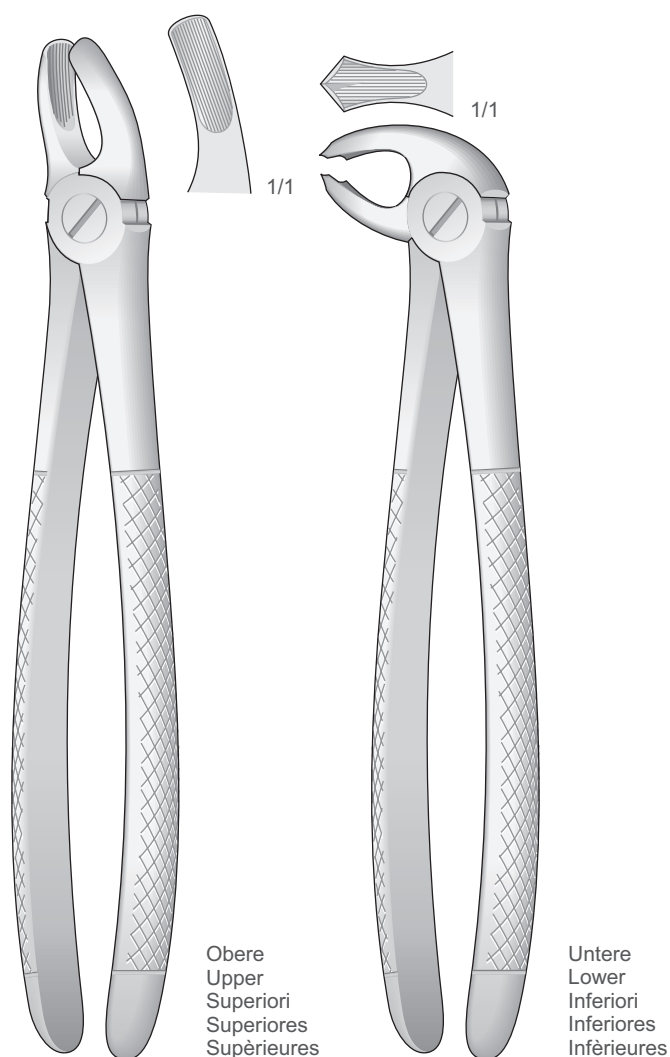
Schneidezähne, Eckzähne, Wurzeln  
Incisors, bicuspid and roots  
Incisivi, canini e radici  
Incisivos, caninos y raices  
Incisives, canines et racines

Molaren  
Molars  
Molari  
Molares  
Molaires



MEAD  
MD-1

MEAD  
MD-3



MEAD  
MD-2

MEAD  
MD-4

## Extracting Forceps for children, American Pattern

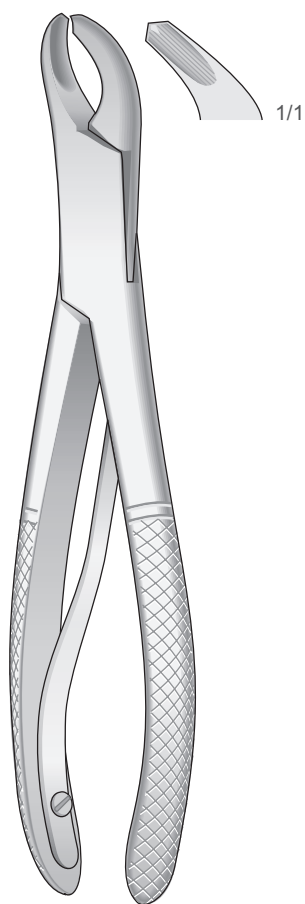
Kinderzahnzangen, Amerikanische Form  
Pinze per estrazione per bambini, Forma Americana  
Forceps dentales para niños, Forma Americana  
Daviers pour enfants, Forme Américaine

Molaren  
Pedo Lower Molars  
Molari  
Molares  
Molaires

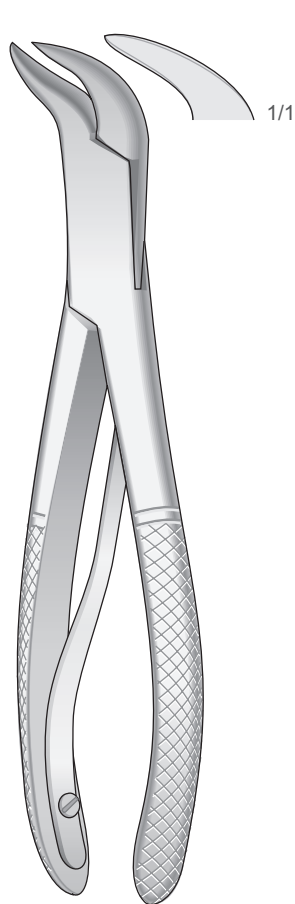
Molaren  
Pedo Lower Molars  
Molari  
Molares  
Molaires

Zähne und wurzeln  
Pedo upper incisors  
Bicuspid and roots  
Denti e radici  
Dientes y raíces  
Dentes et racines

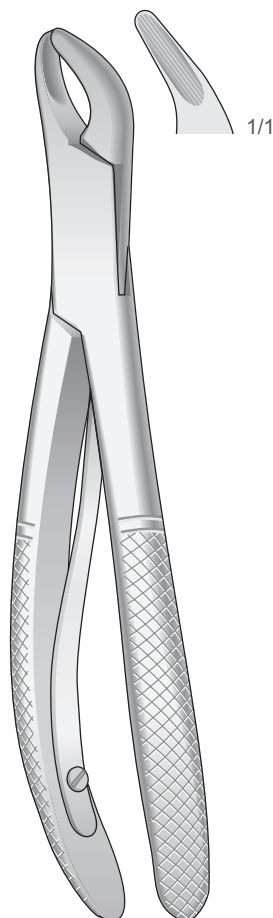
Zähne und wurzeln  
Pedo lower incisors  
Bicuspid and roots  
Denti e radici  
Dientes y raíces  
Dentes et racines



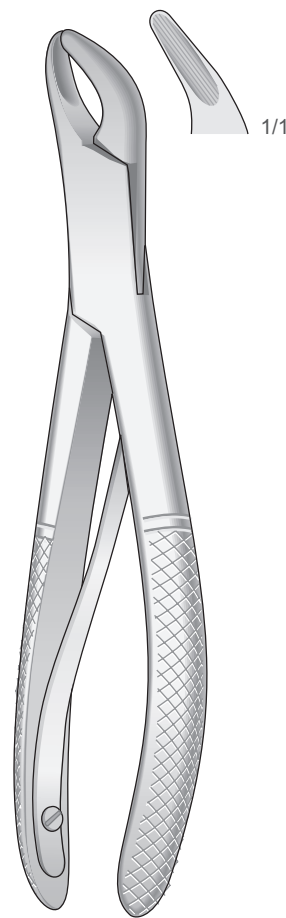
**PEB-17S**  
Fig. 17SK



**PEB-23S**  
Fig. 23SK



**PEB-150S**  
Fig. 150SK



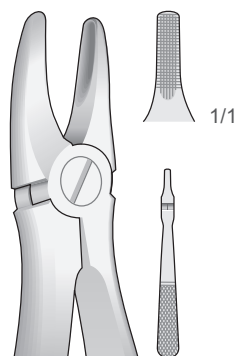
**PEB-151S**  
Fig. 151SK

## Extracting Forceps for children

Kinderzahnzangen  
 Pinze per estrazione per bambini  
 Forceps dentales para niños  
 Daviers pour enfants

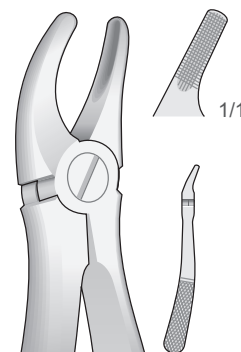
## Forceps

Pinzetten  
 Pinzas  
 Pincas  
 Pinzei



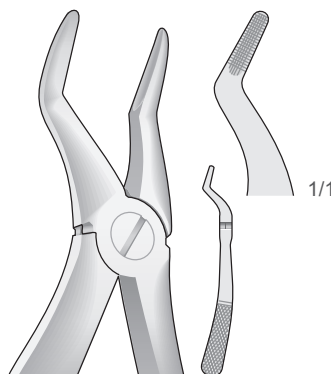
**PEB-1**  
 Fig. 137

Obere Schneidezähne  
 Upper Incisors  
 Incisivi superiori  
 Incisivos superiores  
 Incisives supérieures



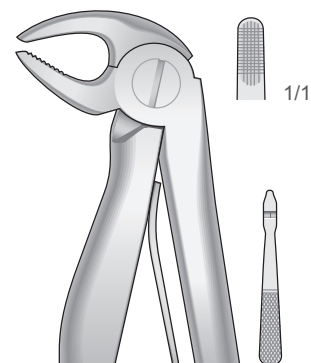
**PEB-2**  
 Fig. 139

Obere Prämolaren  
 Upper Premolars  
 Premolari superiori  
 Premolares superiores  
 Prémolaires supérieures



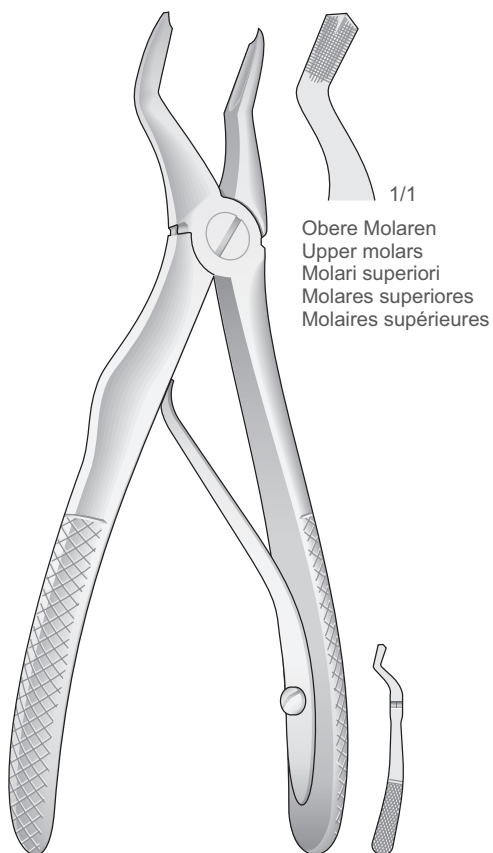
**PEB-4**  
 Fig. 51S

Obere Wurzeln  
 Upper roots  
 Radici superiori  
 Raíces superiores  
 Racines supérieures



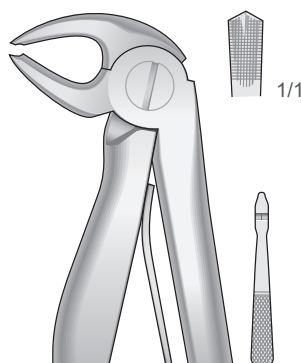
**PEB-5**  
 Fig. 5

Untere Schneidezähne  
 Lower incisors  
 Incisivi inferiori  
 Incisivos inferiores  
 Incisives inférieures



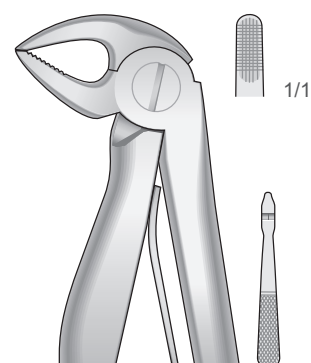
**PEB-3**

Obere Molaren  
 Upper molars  
 Molari superiori  
 Molares superiores  
 Molaires supérieures



**PEB-6**  
 Fig. 6

Untere Molaren  
 Lower Molars  
 Molari inferiori  
 Molares inferiores  
 Molaires inférieures



**PEB-7**  
 Fig. 7

Untere Wurzeln  
 Lower roots  
 Radici inferiori  
 Raíces inferiores  
 Racines inférieures

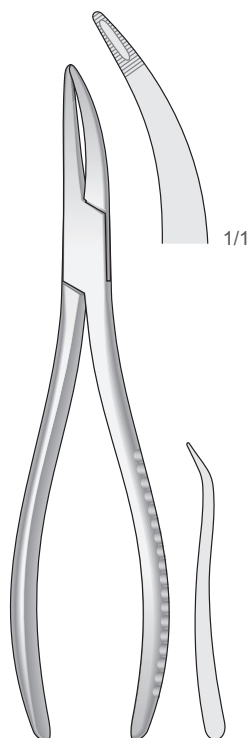
## Root Fragment Forceps

Wurzelfragmentinstrumente

Strumenti per frammenti di radici

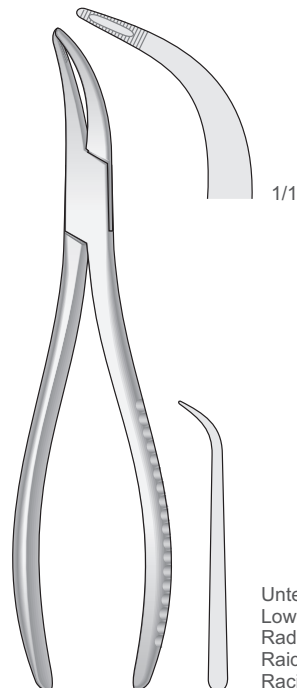
Instrumentos para fragmentos de raíces

Instruments pour fragments de racines



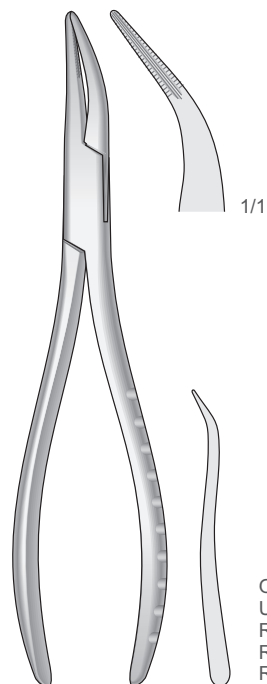
Obere Wurzeln, Universal  
Upper roots, Universal  
Radici superiori, Universale  
Raíces superiores, Universal  
Racines superieures, Universel

**WITZEL  
DK-26**  
170 mm



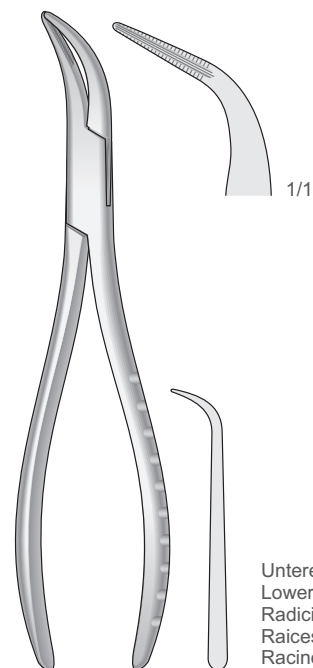
Untere Wurzeln, Universal  
Lower roots, Universal  
Radici inferiori, Universale  
Raíces inferiores, Universal  
Racines inferieures, Universel

**WITZEL  
DK-28**  
165 mm



Obere Wurzeln, Universal  
Upper roots, Universal  
Radici superiori, Universale  
Raíces superiores, Universal  
Racines superieures, Universel

**S-400**  
# 400 (300)  
165 mm



Untere Wurzeln, Universal  
Lower roots, Universal  
Radici inferiori, Universale  
Raíces inferiores, Universal  
Racines inferieures, Universel

**I-401**  
# 401 (301)  
160 mm

## Root Fragment Forceps

Wurzelfragmentinstrumente

Strumenti per frammenti di radici

Instrumentos para fragmentos de raíces

Instruments pour fragments de racines

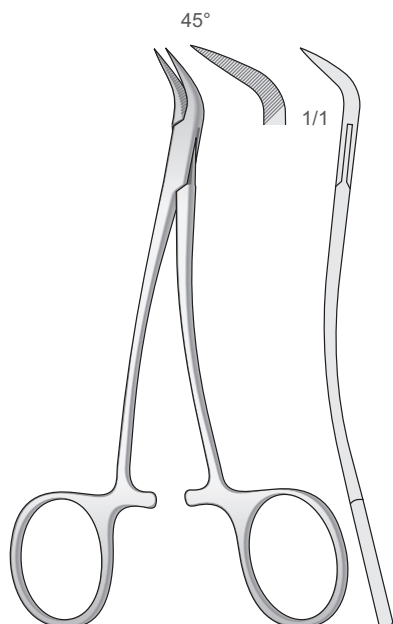
## Forceps

Pinzette

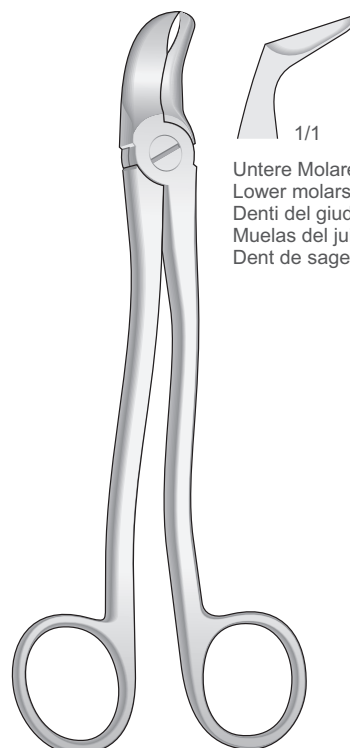
Pinzas

Pinces

Pinzei



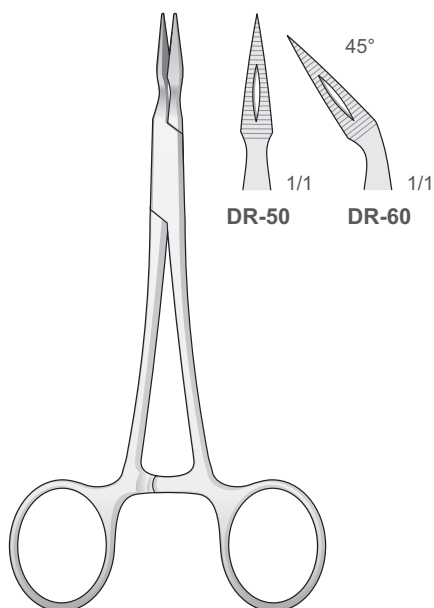
PEET  
DR-40  
120 mm



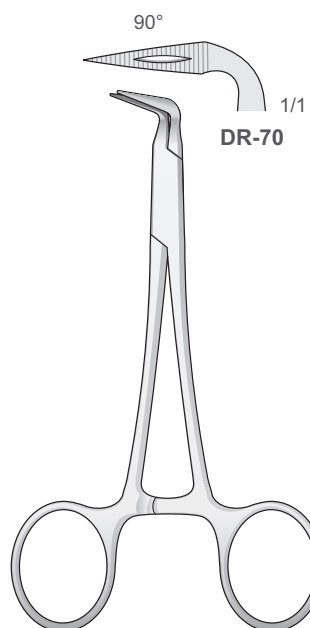
RO-1  
175 mm

Untere Molaren und Weisheitszähne  
Lower molars and wisdom teeth  
Denti del giudizio e molari inferiori  
Muelas del juicio y molares inferiores  
Dent de sagesse et molaires inférieures

Wurzelfragmente  
Root fragments  
Frammenti di radici  
Fragmentos de raíces  
Fragments de racines



STIEGLITZ  
DR-50/DR-60  
140 mm



STIEGLITZ  
DR-70  
120 mm

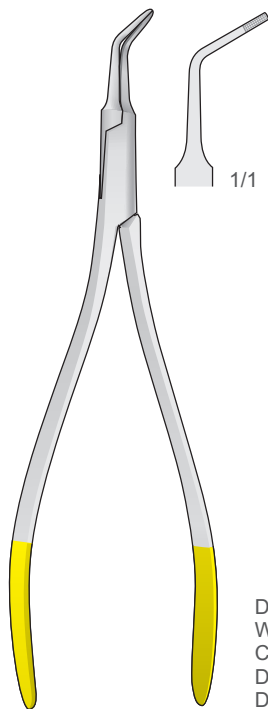
## Root Fragment Forceps

Wurzelfragmentinstrumente

Strumenti per frammenti di radici

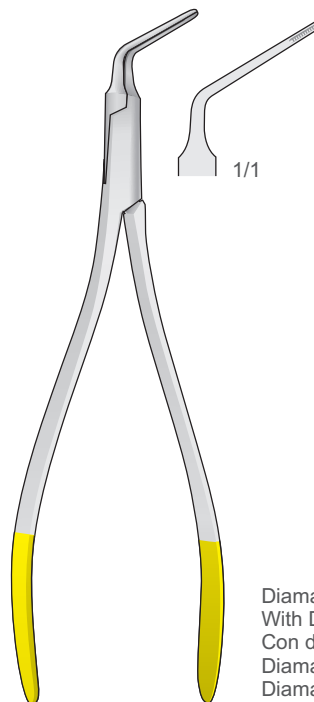
Instrumentos para fragmentos de raíces

Instruments pour fragments de racines



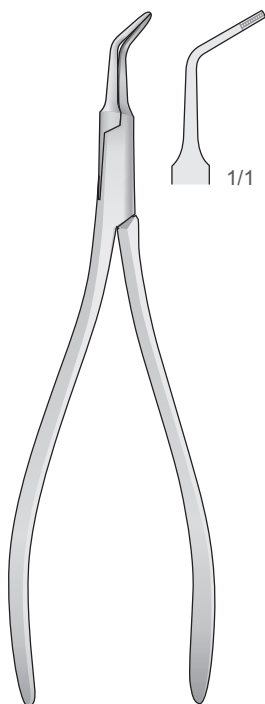
**DA-01M**  
130 mm

Diamantiert  
With Diamond  
Con diamante  
Diamantada  
Diamantées

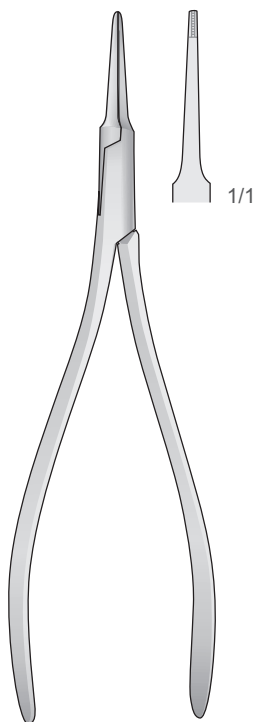


**DA-10**  
130 mm

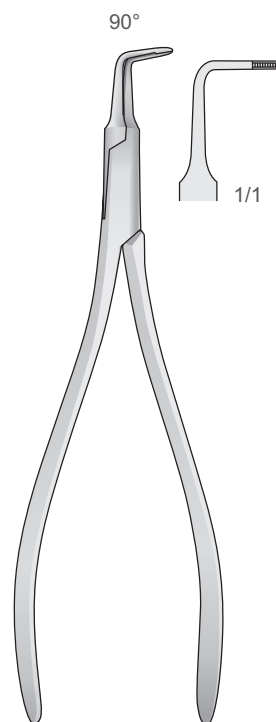
Diamantiert  
With Diamond  
Con diamante  
Diamantada  
Diamantées



**DA-01**  
130 mm



**DA-02**  
130 mm



**DA-03**  
125 mm